
502) 59 y/o presented with new onset supraventricular tachycardia with palpitation, no Hx of SO or chest pain, chest examination normal, oxygen sat in room air = 98% no peripheral edema. Others normal, the best initial investigation:

- a. ECG stress test
- b. Pulmonary arteriography
- c. CT scan
- d. Thyroid stimulating hormone

the correct answer is d

503) Lactating women presented with breast engorgement and tenderness. Your managements:

- a. Warm compressor and continue breast feeding
- b. Dicloxacillin and continue breast feeding
- c. Dicloxacillin and milk expression
- d. Discontinue breast feeding and cold compressor

the correct answer is a. This case is (engorgement of breast) . but if there are redness , swelling , fever this case is (mastitis) and choose b

504) The Fastest route of antipsychotic is:

- a. IM
- b. IV

c. Oral

d. Sublingual

[the correct answer is b](#)

505) While you are in the clinic you find that many patients presents with red follicular conjactivitis (Chlamydia) your management is:

a. Improve water supply and sanitation

b. Improve sanitation and destroying of the vector

c. Eradication of the reservoir and destroying the vector

d. Destroy the vector and improve the sanitation

[the correct answer is a](#)

506) The most important exogenous risk factor for osteoporosis is:

a. Alcohol intake

b. Age

c. Smoking

d. Lack of exercise

[the correct answer is c](#)

507) Patient with family history of coronary artery disease his BMI= 28 came to you asking for the advice:

a. Start 800 calorie intake daily

b. Decrease carbohydrate daytime

c. Increase fat and decrease protein

d. Start with decrease K calorie per kg per week

the correct answer is d

508) Lactating mother newly diagnosed with epilepsy , taking for it phenobarbital you advice is:

- a. Discontinue breastfeeding immediately
- b. Breastfeed baby after 8 hours of the medication

c . Continoue breastfeeding as tolerated

the correct answer is c

-very vague question , some books avoid Phenobarbital during breast feeding if possible. And in American academy of pediatric classified Phenobarbital as adrug that cause major adwers effect in some nursing infant, and should be given to nursing women with cation .

509) Pregnant women has fibroid with of the following is True:

- a. Presented with severe anemia
- b. Likely to regress after Pregnancy**
- c. Surgery immediately
- d. Presented with Antepartum He

the correct answer is b

Fibroids may also be the result of hormones. Reproductive hormones like estrogen and progesterone can stimulate cell growth, causing fibroids to form. During pregnancy, your influx of hormones may cause your fibroids to grow in size. After pregnancy and during menopause most fibroids begin to shrink, due to a lack of hormones.

510) A known case of chronic atrial fibrillation on the warfarin 5 mg came for follow up you find INR 7 but no signs of bleeding you advice is:

- a. Decrease dose to 2.5 mg
- b. Stop the dose and repeat INR next day**

c. Stop warfarin

d. Continue same and repeat INR

the correct answer is b

INR	ACTION
>10	Stop warfarin. Contact patient for examination. MONITOR INR
7-10	Stop warfarin for 2 days; decrease weekly dosage by 25% or by 1 mg/d for next week (7 mg total); monitor INR
4.5-7	Decrease weekly dosage by 15% or by 1 mg/d for 5 days of next week (5 mg total); repeat monitor INR
3-4.5	Decrease weekly dosage by 10% or by 1 mg/d for 3 days of next week (3 mg total); repeat monitor INR.
2-3	No change.
1.5-2	Increase weekly dosage by 10% or by 1 mg/d for 3 days of next week (3 mg total);
<1.5	Increase weekly dose by 15% or by 1 mg/d for 5 days of next week (5 mg total);

511) Patient is a known case of CAD the best exercise:

a. Isotonic exercise

b. Isometric exercise

c. Anaerobic exercise

d. Yoga

the correct answer is c

1-anaerobic exercise (endurance) : for improve cardiac function

2- weight bearing exercise (isometric) : for build muscle strength , bone density

3- stretching exercise : for prevent cramp , stiffness and back pain

512) The mechanism of action of Aspirin:

a. Inhibit cyclooxygenase

b. Inhibit phospholipase A2

c. Inhibit phospholipid D

[the correct answer is a](#)

513) The absolute contraindication of breastfeeding is :

a. Asymptomatic HIV patient

b. Active hepatitis C

c. Pulmonary TB on treatment 3 months

[The correct answer is a](#)

[Absolute contraindication of breastfeeding :](#)

1-Infants with galactosemia.

2-Mothers who use illegal drugs.

3-Mothers infected with HIV, human T-cell lymphotropic virus type I or type II, or who have an active herpes lesion on the breast.

4-Mothers taking any of the following medications: radioactive isotopes, cancer chemotherapy agents, such as antimetabolites

.

514) A boy fell down on his elbow , the lateral x-ray shows:

a. Anterior Pad sign

b. Posterior pad sign

c. Anterior line of humerus intersecting the cubitium

d. Radial line forming 90 degree with cubitium

[the correct answer is A](#)

515) A known case of treated Hodgkin lymphoma (mediastinal mass) with radiotherapy. Not on regular follow up presented with gradual painless difficulty in swallowing and SOB , There is facial swelling and redness : DX

a. SVC obstruction

- b. IVC obstruction
- c. Thoracic aortic aneurysm
- d. Abdominal aortic aneurysm

[The correct answer is a](#)

516) Patient is presented with hand cellulitis and red streaks in the hand and tender axillary lymphadenopathy. This condition is more likely to be associated with:

- a. Malignancy
- b. Pyoderma
- c. Neuropathy
- d. Lymphangitis

[the correct answer is b \(I'm not sure \)](#)

516) Young aged male presented to ER after blunt trauma to Abdomen, CT scan shows intramural hematoma: your management is

- a. Laprotomy with evacuation of the hematoma
- b. Dissection of duodenum
- c. Observation

[the correct answer is c](#)

517) Patient presented with sore throat, anorexia, loss of appetite , on throat exam showed enlarged tonsils with petechi on palate and uvula , mild tenderness of spleen and liver :DX

- a. Group A strep
- b. EBV

[The correct answer is b](#)

518) Patient with GERD has barret esophagus , this metaplasia increase risk of :

- a. Adenocarcinoma
- b. Squamous cell carcinoma

[the correct answer is a](#)

519) Complication of Sleep apnea is :

- a. CHF
- b.

[the correct answer is a](#)

sleep apnea : Hypoxic pulmonary vasoconstriction → PAH → Cor Pulmonale → CHF

complication of sleep apnea : sleep apnea increases health risks such as cardiovascular disease, high blood pressure, stroke, diabetes, clinical depression, weight gain and obesity. The most serious consequence of untreated obstructive sleep apnea is to the heart. In severe and prolonged cases, there are increases in pulmonary pressures that are transmitted to the right side of the heart. This can result in a severe form of congestive heart failure (*cor pulmonale*).

520) Which of the following medication can be used as prophylaxis in appendectomy:

- a. Cephalexin
- b. Ceftriaxone
- c. Metronidazole
- d. Vancomycin
- e. Ampicillin

[The correct answer is c](#)

1st line of antibiotic : 1- cefoxitin 2- cefotetan

2nd line of treatment : 1- metradinazole 2- ampicikkin-sulbactam

521) Which of the following prognostic factor for SLE:

- a. ANA levels
- b. Sex
- c. Age
- d. Renal involvement

[The correct answer is d](#)

522) The most common site for osteomyelitis is:

- a. Epiphysis
- b. Diaphysis
- c. Metaphysis
- d. Blood flow

[The correct answer is c](#)

523) In “holding breath holding” which of the following True:

- a. Mostly occurs between age of 5 and 10
 - b. Increase Risk of epilepsy
 - c. A known precipitant cause of generalized convulsion
 - d. Diazepam may decrease the attack
-

Breath holding spells are the occurrence of episodic apnea in children, possibly associated with loss of consciousness, and changes in postural tone. [They are most common in children between 6 and 18 months and usually not present after 5 years of age.](#) They are unusual before 6 months of age. A positive family history can be elicited in 25% of cases. It may be confused with a seizure disorder.

There are four types of breath holding spells.

1-The most common is termed *simple breath holding spell*, in which the manifestation is the holding of breath in end expiration. There is no major alteration of circulation or oxygenation and the recovery is spontaneous.

2-The second type are the **Cyanotic breath-holding spells**. They are usually precipitated by anger or frustration although they may occur after a painful experience. The child cries and has forced expiration sometimes leading to cyanosis (blue in color), loss of muscle tone, and loss of consciousness. The majority of children will regain consciousness. The child usually recovers within a minute or two, but some fall asleep for an hour or so. Physiologically, there is often hypocapnea (low levels of carbon dioxide) and usually hypoxia (low levels of oxygen. There is no "post ictal" phase (as is seen with seizures), no incontinence, and the child is fine in between spells. EEGs are normal in these children. There is no relationship to the subsequent development of seizures or cerebral injury as a consequence of breath holding spells.

3-In the third type, known as **Pallid breath-holding spells**, the most common stimulus is a painful event. The child turns pale (as opposed to blue) and loses consciousness with little if any crying. The EEG is also normal, and again there is no post ictal phase, nor incontinence. The child is usually alert within a minute or so. There may be some relationship with adulthood syncope in children with this type of spell.

4- A fourth type, known as **Complicated breath-holding spells**, may simply be a more severe form of the two most common types. This type generally begins as either a cyanotic or pallid spell that then is associated with seizure like activity. An EEG taken while the child is not having a spell is still generally normal.

DX: clinical , good history include sequence of event , lack of incontinence and no post ictal phase. Treatment : reassurance and iron.

524) Infant brought by the mother that noticed that the baby has decreasing feeding , activity and lethargic On examination febrile(39), tachycardic ,his bp 75/30, with skin rash . DX:

a. Septic shock

Q not complete

525) Old patient newly diagnosed with hyperthyroidism presented with (hyperthyroidism symptoms) The best initial symptomatic treatment is:

a. BB (beta-blocker)

b. PTU

The correct answer is a

526) Infant presented with hemangioma on the back . your management is:

- a. **Intralesional injection of corticosteroids**
- b. Topical corticosteroids
- c. Excise of the lesion

527) Pregnant lady , 34 wk GA , presented with vaginal bleeding more than her menstruation. On examination , cervix is dilated 3 cm with bulging of the membrane, fetal heart rate = 170 bpm . The fetus lies transverse with back facing down . us done and shows that placenta is attached to posterior fundus and sonotranulence behind placenta. Your management is :

- a. **C/S**
- b. Oxytocin
- c. Tocolytics
- d. Amniotomy

[the correct answer is a](#)

528) Infant with congenital hip dislocation:

- a. **+ve click in flexion ,abduction**
- b. The only treatment is surgery
- c. Not reduced with flexion and abduction of the hip

[the correct answer is a . this is ortolani test](#)

529) In irritable bowel S. the following mechanism ?contraction and slow wave myoelectricity seen in:

- a. **Constipation**
- b. Diarrhea

[the correct answer is a](#)

529) Which is not found in coarctation of the aorta:

- a. Upper limb hypertension
- b. Diastolic murmur heard all over precordium
- c. Skeletal deformity on chest x-ray

the correct answer is a (I'm not sure)

530) Female patient presented with tender red swelling in the axilla with history of repeated black head and large pore skin in same area: ttt is

- a. Immediate surgery
- b. Topical antibiotic
- c. Cold compressor
- d. Oral antibiotic

531) In indirect hernia the relation of the sac to the cord structure is:

- a. Anteromedial
- b. Anterolateral
- c. Posteromedial
- d. Postrolateral

the correct answer is b

532) The most common cause of croup is:

- a. Parainfluenza
- b. Influenza

the correct answer is a

533) kwashikor disease usually associated with :

a. decrease protein intake, decrease carbohydrate

b. increase protein , increase carbo

c. decrease protein , increase carbo

the correct answer is c. in the book, written there is decrease protein and adequate amount of carbohydrate, but with this only MCQs the answer is c

534) in cachectic patient, the body utilize the proteins of the muscles :

a. to provide Amino acid and protein synthesis

b. to maintain bloodflow to vital organ

c. to increase body fat

the correct answer is a (I'm not sure)

535) patient is complaining of memory loss. Alzheimer disease is diagnosed what is the cause of this:

a. brain death cell

Q not complete

536) Parents brought their baby to you who is on bottle feeding. On exam whitish lesion on either side of teeth seen with blackish lesion on maxillary incisors and second molar teeth. There is history of leaving the baby with bottle in his mouth during sleeping. The Dx:

a. Nursery dental caries

b. Gingivostomatitis

the correct answer is a

537) Which of the following medication if taken need to take the patient immediately to the hospital:

a. Penicillin

b. diphenhydramine

c. OCPs

d. Quinine or Quinidine

the correct answer is d (I'm not sure) , quinidine is antiarrhythmia .

538) 43 y/o female presented with severe DUB other examination normal . your management is

- a. D &C
- b. Ocps
- c. Hysterectomy
- d. Blood transfusion

the correct answer is a

539) Baby with vesicles on the face and honey comb crust which of the following organism cause it: **Staph aureus**

540) Female patient presented with migraine headache which is pulsatile, unilateral , increase with activity . Doesn't want to take medication. Which of the following is appropriate:

- a. Bio feedback
- b. TCA
- c. BB

the correct answer is a

Biofeedback has been shown to help some people with migraines. Biofeedback is a technique that can give people better control over body function indicators such as blood pressure, heart rate, temperature, muscle tension, and brain waves. The two most common types of biofeedback for migraines are thermal biofeedback and electromyographic biofeedback.

541) Infant born with hemangioma on the rt eyelid what is appropriate time to operate to prevent amblyopia:

- a. 1 day
- b. 1 week
- c. 3 months
- d. 9 months

difficult Q. but may be the correct answer is b or c

542) Young patient on anti TB medication presented with vertigo which of the following drug cause this:

- a. **Streptomycin**
- b. Ethambutol
- c. Rifampicin

the correct answer is a , streptomycin cause 8th nerve damage.

543) The CPR for child is

- a. 30 chest compression 2 ventilation ... (Lone rescuer)
- b. **15 chest c 2 ventilation ... (2 or more rescuers)**
- c. m15 chest compression 1 ventilation

the correct answer is a

544) Picture show large ulcer over medial side of the leg . what is your management

- a. Shave biopsy
- b. **Elevate the legs and stocking**
- c. Topical steroids

the correct answer is b

545) 2months infant with white plaque on tongue and greasy ,past h/o clamydia conjunctivitis after birth treated by clinamycin what is ttt:

- a. Oral nystatin
- b. Topical steroids
- c. Topical acyclovair
- d. Oral tetracycline

the correct answer is a. oral nystatin : antifungal

546) child rt ear pain and tenderness on pulling ear , no fever , O/E inflamed
odemateous rt ear canal with yellow discharge >>>>>>>>dx:

- a. Otitis media
- b. Otitis externa
- c. Cholesteatoma

the correct answer is b

547) 34y female with HIV pap smear negative, about cervical cancer screening :

- a. After 3m if negative repeat after 6m
- b. After 6m annually
- c. After 1y.....annually

The correct answer is c

548) female about 30y with breast cancer (given cbc –chem. And reavel low hb and
hematocrite....) what is the next step in mangment:

- a. Staging
- b. Lumpectomy
- c. Mastectomy
- d. chemotherapy

the correct answer is a

549) child with moderate persistant BA On bronch.dilat inhaler. Presented with acute
exacerbation what will you add in ttt:

- a. Corticosteroid inhaler
- b. Ipratropum bromide inhaler

the correct answer is b

550) about head and neck injury :

- a. Hoarsness of voice and stridor can occure with mid facial injury

- b. Tracheostomies contraindicated**
- c. Facial injury may cause upper air way injuries**

551) lactating women 10 days after delivery developed fever ,malaise, chills tender Lt breast with hotness and small nodule in upper outer quadrant with axillary LN .Leucocytic count was $14 \times 10^9/L$ dx:

- a. Inflammatory breast cancer
- b. Breast abscess**
- c. Fibrocystic disease

[the correct answer is b](#)

552) 70y male with osteoporosis the T score of bone densometry would be :

- a. -3.5
- b. -2.5**
- c. 1
- d. 2
- e. 3.5

[the correct answer is b](#)

553) child with epistaxis..... management:

- a. Compression on nose and leaning forward**
- b.backward

[the correct answer is a](#)

554) scenario about female underwent abdominal operation she went to physician For check..... U/S reveal metal thing inside abdomen (a.e missed during operation) What will you do :

- a. Call the surgeon and ask him what to do
- b. Call attorney and ask about legal action
- c. **Tell her what you found**
- d. Tell her that is one of possible complications of operation
- e. Don't tell her what you found

The correct answer is c

555) male ptn with scaly fine papular rash on fornt of scalp,nose and retroauricular.....(i think tinea capitis) ttt is:

- a. **Ketoconazole cream...**
- b. Oral augmentin
- c. cream

the correct answer is a

556) All can cause gastric ulcer except:

- a- **Tricyclic antidepressant.**
- b- Delay gastric emptying.
- c- Sepsis.
- d- Salicylates.
- e- Gastric outlet incompetent.

The correct answer is a

Tricyclic antidepressant use in treatment of peptic ulcer.

557) 48year old female lost her menstruation for 2 cycles, the method of contraception is condom, examination was normal except for dusky discoloration of the cervix. What u will do next:

- a. Progesterone challenge.
- b. **Beta HCG.**
- c. Pelvic u/s

The correct answer is b

558) ttt of yeast vaginitis: Clotrimazole , Fluconazole , Ketokonazole

Treatment of yeast vaginitis (candida albicans) : topical azole or PO fluconazole , oral azole should be avoided in pregnant.

559) 15 y/o female complaining of pain during menstruation, not sexually active, medical hx unremarkable, physical examination normal, how to treat:

- a- NSAID.
- b- Danazole.
- c-

The correct answer is a

560) What is true about alpha blocker:

- a. Causes hypertension.
- b. Worsen benign prostatic hyperplasia.
- c. Cause tachycardia.
- d-

the correct answer is c

alpha blocker :cause orthostatic hypotension and tachycardia.

561) cyclic menstruation that increase in frequency:

- a. Polymenorrhea.
- b. Hypermenorrhea.
- c. Menorrhagia.
- d. Dysmenorrhea.
- e.

The correct answer is a

Polymenorrhea : frequent menstruation (< 21 day cycle)

Hypermenorrhea or menorrhagia : abnormally heavy and prolonged menstrual period at regular intervals . more than 80 ml of blood loss per cycle or prolonged bleeding , more than 8 days.

Oligomenorrhea : increase length of time between menses (35-90 days b\w cycle)

Metrorrhagia : bleeding bwtween period.

Menometrorrhagia : excessive and irregular bleeding.

562) A pregnant lady came to you to screen her fetus for down syndrome, what is the best method:

- a. Amniocentesis. + Karyotyping
- b. Choriocentesis.
- c.

the correct answer is a

563) What is the most common chromosomal abnormality?

- a. Trisomy 13
- b. Trisomy 21

the correct answer is b

-down syndrome (trisomy 21) is the most common chromosomal abnormality.

564) Best 2 test to screen for hepatocellular carcinoma:

- a. Liver biopsy and alpha-fetoprotein.
- b. Liver ultrasound and alpha-fetoprotein.
- c. Abdomen CT and
- d.

The correct answer is b

565) A child came to ER with fever, stridor, ... , x-ray showed swollen epiglottitis, in addition to oxygen, what u will do?

- a. Throat examination.
- b. An emergency tracheostomy.
- c. Endotracheal intubation.
- d. Nasopharyngeal intubation.

The correct answer is c

566) 24 y/o female newly diagnosed type 2 DM, she is wearing glasses for 10 years, how frequent she should follow with ophthalmologist:

- a. Every 5 years.
- b. Annually

The correct answer is b

-for type 1 diabetic : retina screening annually beginning 5 years after onset of diabetes, general not before onset of puberty.

- for type 2 diabetic : screening at the time of diagnosis then annual

567) What is the initial management for a patient newly diagnosed knee osteoarthritis.

- a. Intra-articular corticosteroid.
- b. Reduce weight.
- c. Exercise.
- d. Strengthening of quadriceps muscle.

The correct answer is b

568) A lady came to your clinic said that she doesn't want to do mammogram and preferred to do breast self- examination, what is your response?

- a- **Mammogram will detect deep tumor.**
- b- Self-examination and mammogram are complementary.
- c- Self-examination is best to detect early tumor

answer is a (I'm not sure because MCQs not complete and depend on age of pt.

569) What is the best frequency for breast self-examination?

- a. Daily.
- b. Weekly.
- c. **Monthly.**
- d. Annually.

The correct answer is c

570) Patient with left bundle branch block will go for dental procedure , regarding endocarditis prophylaxis:

- a. No need
- b. **Before procedure.**
- c. After the procedure.
- d.

The correct answer is b

571) classical characteristic for genital herpes.

Painful ulcers & vesicles

572) most common vaginal bleeding :

- a. cervical polyps
- b. **menstruation**
- c. ????

only with these MCQs , the correct answer is b

573) best stimulant for breast milk secretion:

- a. **breast feeding**
- b. oxytocin
- c. ???

the correct answer is a

574) child with aspirin intake overdose ...what kind of acid base balance:

- a. metabolic alkalosis wt respiratory
- b. **metabolic acidosis wt respiratory alkalosis**
- c. **respiratory alkalosis with metabolic acidosis**
- d. respiratory acidosis with metabolic alkalosis

The correct answer is c

Aspirin toxicity : in early stages, salicylate will stimulate respiratory center → ↑RR → respiratory alkalosis that will be compensated by metabolic acidosis. In late stage, it will interfere with COH, fat, & protein metabolism as well as Oxidation phosphorylation lead to ↑ lactate, pyrovate, & keton bodies. All will lead to ↓pH. Signs & symptoms includes: nausea, vomiting, ↑RR, ↑temp, ↑HR, sweating, cerebral or pulmonary edema, & coma. +ve anion gap. TTT: hydration, correct K+, gastric lavage or activated charcoal, urine alkalization, hemodialysis)

575) therapeutic range of INR :

- a. 2.5-3.5
- b. **2.0-3.0**
- c. ???

The correct answer is b

576) q about antidepressant:

- a. **start single type even patient have severe depression**
- b. start any one of them they all have the same efficacy
- c. stop the medication after 2 weeks if no improvement

The correct answer is a

577) patient with depression started on amitriptyline , he had headache or dizziness , vomiting?? im not sure what exactly was the symptoms

- a. change to SSRI
- b. ??

Q not complete , but amitriptyline is TCA .

578) patient had hoarseness of voice for 3 weeks... next to do:

- a. throat swab
- b. laryngoscopy**
- c. ???

The correct answer is b , I'm not sure because MCQs are not complete.

579) single diagnostic for stroke:

- a. high cholesterol
- b. high systolic blood pressure**

the correct answer is b , I'm not sure , but with these mcqs , b is correct.

580) unfavorable prognosis for schizophrenia:

- a. family Hx**
- b. failed marriage
- c. adolescent age?? not sure
- d. presence of psychosis

the correct answer is a

581) Rt lung :

- a. have 1 fissure
- b. contain 7 segments
- c. ??? read about lung anatomy segment names!!

Rt lung has 3 lobes & 10 segments (medial basal segment only in inf. lobe of Rt lung)
Lft lung has 2 lobes & 9 segments (lingular segments in lft lung)

582) q about specificity:

- a. test is +ve in disease population

- b. test is +ve in healthy poplation
- c. test is -ve in diseased population
- d. test is -ve in healthy population

The correct answer is d

583) stage 3 colon ca → Give Chemo ASAP

584) patient with upper abdominal pain, nausea vomitting,with back pain, he is smoker for long time daily, fecal fat was +ve

- a. acute pancreatitis
- b. chronic pancreatitis
- c. pancreatic CA

The correct answer is b

585) in school, 10 of patient had the dis of the first week , then 30 pt. had the dieses the next week , the percentage infection of this school is:

- a. 10%
- b. 20%
- c. 30%
- d. 40%

Q is not clear or not complete, but I think the correct answer is b.

586) patient had headche describe it as aband around his head, increase with stress and , i dont remeber the ques DX is:

- a. tension headache
- b. migraine
- c. cluster headache

The correct answer is b

587) Patient was presented by bollus in his foot , biopsy showed sub dermal lysis , fluorescent stain showed IgG , what is the most likely diagnosis :

- A. Bolus epidermolysis .
- B. Pemphigoid vulgaris .
- C. Herpetic multiform .
- D. Bullous pemphigoid .

The correct answer is d

Bullous Pemphigoid

An acquired blistering disease that leads to separation at the epidermal basement membrane. It is most commonly seen in patients 60–80 years of age. Its pathogenesis involves antibodies that are developed against the bullous pemphigoid antigen, which lies superficially in the basement membrane zone (BMZ). Antigen-antibody complexes activate complement and eosinophil degranulation that provoke an inflammatory reaction and lead to separation at the BMZ. The blisters are stable because their roof consists of nearly normal epidermis.

HISTORY/PE

Presents with firm, stable blisters that arise on erythematous skin, often preceded by urticarial lesions. Nikolsky's sign is \square . The blisters form crusts and erosions (see Figure 2.2-7). Mucous membranes are less commonly involved than in the case in pemphigus.

DIAGNOSIS

Diagnosed according to the clinical picture. Skin biopsy shows a subepidermal blister, often with an eosinophil-rich infiltrate. Immunofluorescence demonstrates linear IgG and C3 immunoglobulin and complement at the dermal-epidermal junction.

TREATMENT

Systemic corticosteroids. Topical corticosteroids can help prevent blister formation when applied to early lesions.

.....

588) Patient was presented by difficulties of breathing from one side of his nose , on examination there was erythematous swelling , what is the best initial treatment :

- A. Decongestant .
- B. Steroid .
- C. Sympathomimetics . ??

The correct answer is c (I'm not sure)

Explain: this swelling might be nasopharyngeal angiofibroma which is highly vascular swelling & prone to epistaxis, so to decrease the size we might use local or systemic decongestants which are sympathomimetics, so answer is not clear.

589) Patient with cystic nodule (acne) and scars , what is the best treatment :

- A. Retinoin .
- B. Erythromycin .
- C. Doxycyclin .

The correct answer is a (I'm not sure)

this seems to be an advanced inflammatory stage of acne since there r scars so if the retinoid meant here is systemic (isotretinoin) so it will be the choice. If topical it will not be effective as it is effective only in the non-inflammatory stage (comedones). Both erythromycin (local) & doxycycline (systemic) can be used but in advanced stage systemic is better.

590) Patient was presented by constipation, vomiting, abdominal distension, with old scar in the lower abdomen, x ray showed dilated loops with air in the rectum, what is the best initial management :

- A. **NGT decompression, and IV line.**
- B. Rectal decompression and antibiotics.
- C. Suppositories.

The correct answer is a

this is a case of intestinal obstruction due to adhesions from previous abdominal surgery (commonest cause) so the initial treatment would be decompression of the intestine & replace lost fluids

591) Which of the following is not living vaccine :

- A. **Hepatitis B.**
- B. MMR.
- C. Oral polio
- D. BCG

The correct answer is a

Hepatitis B is the only vaccine prepared by genetic engineering so its not living vaccine.

592) Six years old child was born to a mother with hepatitis B, he does not received any vaccines before, what you will give now :

- A. DTP, MMR, Hib
- B. DTP, MMR.
- C. DT, MMR, Hib
- D. **DT, MMR.**

The correct answer is d

both Pertussis & H.influenza vaccine are not needed after 1 year of age.

593) Which of the following describes the end of the early inflammatory phase .

- A. Formation of eschar .
- B. Formation of ground base of collagen .
- C. The end of angiogenesis .

The correct answer is c

594) Female patient , known case of VitD deficiency , smoking , and recurrent fall, which of the following is the greatest exogenous risk for osteoporosis :

- A. Advanced age .
- B. Recurrent fall .
- C. Vit D .
- D. Smoking .

The correct answer is c

Advanced age & female gender are the most important factors for osteoporosis but they are endogenous. Smoking is an independent exogenous risk factor for osteoporosis

595) Blood sugar in DM type 1 is best controlled by :

- A. Short acting insulin .
- B. Long acting .
- C. Intermediate .
- D. Hypoglycemic agents .
- E. Basal and bolus insulin .

The correct answer is e

Very vague question. We can exclude hypoglycemic agents. **Short acting insulin** is best in emergencies like DKA as it can be given IV. We can use either long acting alone daily or a mixture of short & intermediate acting insulin daily. **Basal & bolus , (short acting + intermediate or long)**, bolus' of short-acting or very-short-acting insulin before meals to deal with the associated rise in blood-sugar levels at these times. In addition, they take an evening injection of long- or intermediate-acting insulin that helps normalise their basal (fasting) glucose levels. This offers greater flexibility and is the most commonly adopted method when intensified insulin therapy is used to provide optimal glycaemic control.

596) Which of the following is true regarding perths disease :

- A. Commonly seen between 11-16 years of age .
- B. Always unilateral .
- C. **May present by painless limp .**
- D. Characteristically affect the external rotation of hip .
- E. More in female .

The correct answer is c

Perthes disease (Leg-Calve perthes disease) is a condition affecting the hip joint where there is degenerative avascular necrosis of the femoral head. It affects children aged 3-12 years & is more common in males. It is most commonly but not always unilateral (85% is unilateral). It presents mainly by severe hip pain & limping that increases by movement but it can present by painless limp. It characteristically affects the internal rotation & abduction of the hip & limits these movements.

597) Which of the following is true regarding gastric lavage :

- A. Patient should be in the right lateral position .
- B. **It is not effective after 8 hours of aspirin ingestion .**

The correct answer is b

lavage is effective only 1 hour after ingestion of any poison. After that its ineffective

598) SSRI was prescribed to a patient with depression , the effect is suspected to be within :

- A. One day .
- B. Two weeks .
- C. **Three to four weeks .**

The correct answer is c

Allow 2 – 6 weeks to take effect , and treat for > 6 months

599) Randomized controlled study will be stronger by :

- A. Systemic >>>>
- B. Following at least 50 % of the participant .

???????

600) Partner lost his wife by AMI 6 months ago , presented by loss of appetite , low mood , sense of guilt , what is the diagnosis :

- A. **Bereavement .**
- B. Major depression episode .

The correct answer is a

- Major depression is a psychiatric condition that occurs regardless of events that happen in life, while normally most people would have bereavement after death of a close person.

601) An adult was presented by sore throat , congestion , fatigue , petechia in soft palate , tender spleen , and liver , what is the most likely diagnosis :

- A. **EBV .**

Only 1 choice?

This could be Rubella infection as petechia in soft palate (Forschheimer spots) occur in rubella also. But liver & spleen affection are more common in EBV. Also since it is an adult then we might suspect leukemia as the cause.

602) Patient was presented by blepharitis , acne roseca , but no keratitis , what is the best treatment :

- A. Topical chlorophenicol .
- B. Topical gentamicin .
- C. Oral doxycyclin .

[The correct answer is c](#)

603) Diabetic patient was presented by spastic tongue , dysarthria , spontanous crying what is the most likely diagnosis :

- A. Parkinson .
- B. Bulbar palsy .
- C. Pseudobulbar .
- D. Myasthenia gravis .

[The correct answer is c](#)

This is a bit tricky. Bulbar palsy is the LMNL of the last 4 CN, while pseudobulbar palsy is the UMNL of the last 4 CN. So spasticity of tongue is UMNL. But Diabetes causes LMNL of cranial nerves due to peripheral neuropathy. So maybe the cuase here is CNS affection due to atherosclerosis from macroangiopathy of diabetes.

604) Which of the following is describe the normal developmental stage for 6 months old child :

- A. Sits without support .
- B. Rolls front to back . (7-8 months)
- C. No head lag . (3 months)
- D. Stand alone . (1 year)

[The correct answer is a](#)

605) Which of the following personality is characterized by inflexibility , perfectionism ?

- A. OCD .
- B. **Not otherwise specified .**
- C. Narcissistic .

The correct answer is b

Obsessive compulsive personality disorder is different from obsessive compulsive disorder and is characterized mainly by perfectionism while OCD is characterized by repetitive actions due to compulsion. if OCPD is present in the choices it would be the answer.

.....

606) What is the commonest cause of otorrhea :

- A. **Acute otitis media .**
- B. Basal skull fracture .
- C. External otitis .

The correct answer is a

.....

607) Patient was presented by ear pain , red tympanic membrane , apparent vessels , with limited mobility of the tympanic membrane , what the most likely diagnosis :

- A. **Acute otitis media .**
- B. Tympanic cellulitis .
- C. Mastoiditis .

The correct answer is a

.....

608) What is the management of acute congestive glaucoma :

- A. **IV acetazolamide and topical pilocarpine . (true)**
-

609) Eight years old child with late systolic murmur best heard over the sterna border , high pitch , crescendo , decrescendo ,>> diagnosis is :

- A. Physiological murmur .
- B. Innocent murmur .

- C. **Ejection systolic murmur** .
- D. Systolic regurgitation murmur .

The correct answer is c (I'm not sure)

610) Child was presented by coryza , skin rash , conjunctivitis , and multiple spots in the mouth :

- A. **Measles** .
- B. Rubella .

The correct answer is a.

Measles : due to conjunctivitis which is not present in rubella

611) Which of the following could be seen in patient with bulimia :

- A. **Hypokalemia** .
- B. Metabolic acidosis .

The correct answer is a

bulimia is aka binge eating which means the patient eats a lot then does forced vomiting so there is loss of acids & electrolytes which leads to hypokalemia & metabolic alkalosis.

612) Maximum spinal height is reached after menarche by how many years ?

- A. Months .
- B. Two years .
- C. **Three years** .

The correct answer is c

menarche is at 12-14 years and maximum height is about 17 years

613) Pregnant lady 34 weeks of gestation presented by vaginal bleeding , which of the following is relevant to ask about :

- A. **Smoking .**
- B. Desire of future pregnancy .
- C. The result of last pap smear .
- D. Hx of vaginal irritation .

The correct answer is a , because smoking is an important risk factor for antepartum he

614) Female patient with marginal placenta previa , with 6 cm dilated cervix , what is your management :

- A. **Fetal monitoring .**
- B. Delivery if fully dilated .
- C. Tocolytics >

The correct answer is a (I'm not sure)

I couldn't find the answer correctly so based upon the given data, fetal monitoring is a must in any case of high risk pregnancy. Also as the PP is marginal, there is possibility of delivery without severe PPH and the cervix is already dilated.

615) Which of the following drugs increase the survival in a patient with heart failure :

- A. Beta blocker .
- B. **ACE inhibitors .**
- C. Digoxin .
- D. Nitrites .

The correct answer is b

New updated information. As ACE inhibitors inhibit aldosterone which if present in high concentrations causes modification of the cardiac myocytes in the long term.

616) Elderly patient presented by SOB , rales in auscultation , high JVP , +2 lower limb edema , what is the main pathophysiology :

- A. **Left ventricular dilatation .**
- B. Right ventricular dilatation .
- C. Aortic regurgitation.
- D. Tricuspid regurgitation .

The correct answer is a (cofuuuuuuuse)

Difficult question. Here we have both symptoms of Lft ventricular failure (SOB, Rales) & Rt ventricular failure (High JVP & LL edema). So, more commonly lft ventricular failure leads to rt ventricular failure due to overload and not vice versa . so the most correct is Lft ventricular dilatation.

617) Patient with high output fistula , for which TPN was ordered , after 2 hours of the central venous catheterization , the patient become comatose and unresponsive , what is the most likely cause :

- A. Septic shock .
- B. **Electrolytes imbalance .**
- C. Delayed response of blood mismatch .
- D. Hypoglycemia .
- E. Hypernatremia .

The correct answer is b

618) Female patient presented by tender mass below the axilla , with previous history of pores and black heads in that's area <<< what is your management :

- A. **Go to surgery immediately .**
- B. Oral antibiotics .
- C. Topical antibiotics .
- D. Steroid .

The correct answer is a , This is mostly an infected abscess.

619) Child was presented by erythema , and swelling in his hand after 18 hours of bee sting , what is your management in this case :

- A. Epinephrine .
- B. Antihistaminic drugs .
- C. Hospitalization .

The correct answer is b

18 hours is a long duration so its unlikely to be anaphylactic shock & more likely a regular reaction to bee stings so antihistaminics is the best solution

620) Which of the following is true regarding metformin :

- A. Main complication is hypoglycemia .
- B. Can lead to weight gain .
- C. It suppress the hepatic gluconeogenesis .

The correct answer is c

621) Child was presented by congested throat , coryza , high grade fever , which of the following is true regarding this condition :

- A. Viral > bacterial .
- B. Bacterial > viral .
- C. Antibiotics should be given any way .
- D. It is most likely due to EBV .

The correct answer is b ??????

622) Benign tumors of stomach represent almost :

- A. 7 %
- B. 21 %
- C. 50 %
- D. 90 %

The correct answer is a

623) 60 years old patient presented by recurrent venous thrombosis including superior venous thrombosis , this patient most likely has :

- A. SLE .
- B. Nephrotic syndrome .
- C. Blood group O .
- D. Antiphospholipid syndrome .**

[The correct answer is d](#)

624) Elderly male patient was presented by left lower abdomen tenderness , fever , elevated WBC count , what is the most likely diagnosis :

- A. Inflammatory bowel .
- B. Diverticulitis .**

[The correct answer is b](#)

625) 22 years old male patient was presented by recurrent attacks of diarrhea , constipation , and abdominal pain relieved after defecation , but no blood in the stool , no weight loss : what is the diagnosis :

- A. Irritable bowel Syndrome**

626) Patient was presented by back pain relieved by ambulation , what is the best initial treatment :

- A. Steroid injection in the back .
- B. Back bracing .
- C. Physical therapy .**

[The correct answer is c](#)

627) Patient with long history of constipation presented by painful defecation , followed by bleeding , pain persist for hours after defecation what is the diagnosis :

- A. Anal fissure .
- B. Thrombosed external piles .
- C. Internal hemorrhoid .

The correct answer is a

628) Elderly male patient underwent colectomy for colon cancer in which micrometastasis was detected in the lymph nodes , what is the best explanation :

- A. Good prognosis .
- B. Liver metastasis .
- C. It is sensitive to chemotherapy . (Dukes class C cancer best for chemotherapy)
- D. It is locally advanced .

The correct answer is c

629) IV drug abuser was presented by fever , arthralgia , conjunctival hemorrhage , what is the diagnosis :

- A. Bacterial endocarditis .

630) Female patient was presented by dysuria , epithelial cells were seen urine analysis , what is the explanation in this case :

- A. Contamination .
- B. Renal cause

The correct answer is b

631) Patient was presented by tremor , fever , palpitation , diagnosed as case of hyperthyroidism , what is your initial treatment :

- A. Surgery .
- B. Radio iodine .
- C. Beta blockers . Propylthiouracil .

The correct answer is c , firstly B-blocker then Propylthiouracil because we are afraid of arrhythmias

632) Young female patient presented by pain during the first 2 days of menses ,
menarche was 2 years back , what is your initial treatment :

- A. OCP .
- B. **NSAID .**

The correct answer is b , NSAID it is the best initial treatment for dysmenorrheal

633) Female is planning to get pregnant , she want to get MMR vaccine also , what is
your action :

- A. **Delay the pregnancy 2-3 months after vaccination .**
- B. It is safe during pregnancy .

The correct answer is a

634) Which of the following is true regarding varicella vaccine during breast feeding :

- A. **It is safe .**
- B. No breast feeding except after 3 days of the immunization .

Couldn't find the answer

635) Patient underwent abdominal surgery due to intestinal perforation many years
back , presented by abdominal pain , distension , constipation , what is the best
investigation in this case :

- A. Barium enema .
- B. Ultrasound .
- C. **Small bowel barium study .**

The correct answer is c

636) True negative test is best described as following :

- A. **Not suspected to have the disease who actually do not have .**
-

637) Patient with AMI and multiple PVC , is your treatment for this arrhythmia :

- A. Amiadrone .
- B. No treatment .

638) Adenosine dose should be reduced in which of the following cases :

- A. **Chronic renal failure** .
- B. Patients on thiophylline .

The correct answer is a

639) Which the following is the commonest complication of patient with chronic atrial fibrillation :

- A. Sudden death .
- B. **Cerebra vascular accidents** .

The correct answer is b , due to multiple atrial thrombi

640) Which of the following is most likely seen in case of active glomerulonephritis :

- A. **RBC casts** .
-

641) Target HbA1c is less than :

- A. **6.5**
- B. 8
- C. 9

The correct answer is a

642) Female patient with candida most likely has :

- A. **DM** .
- B. SLE .

The correct answer is a

643) Which of the following indicates good prognosis in schizophrenia :

- A. Family history of schizophrenia .
- B. Gradual onset .
- C. Flat mood .
- D. Prominent affective symptoms .

- E. **No precipitating factors .**

[The correct answer is d](#)

644) Pregnant woman with suspected DVT , what is the best initial investigations :

- A. **Duplex US .**
B. D dimer .
C. Platysomgraphy .
D. Venogram .

[The correct answer is a](#)

645) Which of the following is true regarding crohns disease :

- A. Partial thickness involvement .
B. Fistula formation .
C. Continuous area of inflammation .
D. Mainly involve the recto sigmoid area .

[The correct answer is b](#)

646) Patient serology showed antibodies to the surface antigen for hepatitis B , what is your diagnosis :

- A. Previous infection or immunization .**
B. Chronic carrier .
C. Highly infective .

[The correchr answer is a](#)

647) Young male patient presented by acute scrotal pain , US showed reduced blood flow , what is the diagnosis :

- A. Testicular torsion .**
B. Trauma .

- C. Infection .
- D. Hernia .

[The correct answer is a](#)

648) Female patient is sure that she is pregnant for 2 months , on examination , the uterus is larger than suspected , B-hcg is very high , the doctor diagnosed her as having tumor which is chemo sensitive , what is the diagnosis :

- A. Ovarian cancer
- B. Endometrial cancer .
- C. **Gestational trophoblastic .**

[The correct answer is c](#)

649) Which of the following is true regarding infertility :

- A. It is Failure to conceive withing 6 months . (1 year)
- B. Male factor > female factors . (the reverse)
- C. **It could be due to high prolactin levels .**
- D. Rare to be due anovulation . (common)
- E. Only diagnosed by HSG . (need full lab & imaging investigations)

[The correct answer is c](#)

650) 32 years old female patient presented by irregular menses , menses occurs every two months , on examination every thing is normal , which of the following is the LEAST important test to ask about first :

- A. CBC .
- B. Pelvic US .
- C. **Coagulation profile .**
- D. DHES .

[The correct answer is c](#)

651) Patient with early rheumatoid arthritis , what is your management to decrease the limitation of movement :

- [Do not use analgesics or steroids, use DMARDs like methotrexate or antiTNF, hydroxychloroquine](#)

.....

652) Patient with truncal obesity , easy bruising , hypertension , buffalo hump , what is the diagnosis :

A. Cushing .

.....

653) Patient is known case of cervical spondylolysis , presented by parasthesis of the little finger , with atrophy of the hypothenar muscles , EMG showed cubital tunnel compression of the ulnar nerve , what is your action now :

A. Ulnar nerve decompression .

B. Steroid injection .

C. CT scan of the spine .

[The correct answer is a](#)

654) Well known case of SCD presented by plueritic chest pain , fever , tachypnea , respiratory rate was 30 , oxygen saturation is 90 % what is the diagnosis :

A. Acute chest syndrome .

B. Pericarditis :

C. VOC .

[The correct answer is a , or pneumonia would be more correct if it was the answer](#)

.....

655) Child with hemangioma around the eye , operation should be done within :

A. 1 Week

B. 3 months .

C. 6 months .

[The correct answer is a \(I'm not sure \)](#)

We only fear of reduction in the function of the eye due to hemangioma so it should be removed.

656) Which of the following is the recommended diet to prevent IHD :

- A. Decrease the intake of meat and dairy .
- B. Decrease the meat and bread .
- C. Increase the intake of fruit and vegetables .

????

The correct answer is c

657) Which of the following can lead to polyhydramnios :

- A. Duodenal atresia .
- B. Renal agenesis . → Oligohydramnios
- C. Post term pregnancy . → Oligohydramnios
- D. Diabetes insipidus .

The correct answer is a

658) Adult polycystic kidney disease is inherited as:

- A. Autosomal dominant .
- B. Autosomal recessive .
- C. X linked .

The correct answer is a

659) The best treatment for bacteroid :

- A. Clindamycin .
-

660) You have an appointment with your patient at 10 am who is newly diagnosed DM , you came late at 11 am because you have another complicated patient , what are you going to say to control his anger :

- A. Do not say any thing .
- B. Told him that there is another patient who really need your help .

Q not complete, but may be The correct answer is b

661) Well known case of DM was presented to the ER with drowsiness , in the investigations : Blood sugar = 400 mg/dl , pH = 7.05 , what is your management ?

- A. 10 units insulin + 400 cc of dextrose .
- B. 0.1 unit/kg of insulin , subcutaneous .
- C. NaHCO .
- D. One liter of normal saline .

The correct answer is d

662) What is the best method for history taking :

- A. Yes or no questions .
- B. Open ended .
- C. Silent listening .

The correct answer is b

663) What you will give to prevent hemorrhagic disease of newborns :

- A. Vitamin K .

664) Arterial injury is characterized by :

- A. Dark in color and steady .
- B. Dark in color and spurting .
- C. Bright red and steady .
- D. Bright red and spurting .

The correct answer is d

665) 14 years old girl complaining of painless vaginal bleeding for 2-4 days every 3 weeks to 2 months ranging from spotting to 2 packs per day; she had 2ry sexual

ccc 1 year ago and had her menstruation since 6 months on clinical examination she is normal sexual ccc, normal pelvic exam appropriate action

- a. OCP can be used
- b. You should ask for FSH and prolactin level

c. Don't do anything & explain this is normal

the correct answer is c

666) 4 years old child what can he do

a. Copy square and triangle

b. Speak in sentences

the correct answer is a , if copy square 4 years , but if copu circle 3 years

667) baby can sit without support, walk by holding furniture, Pincer grasp, pull to stand how old is he

a. 8 months

b. 10 months

c. . 12 month

d. 18 month

The correct answer is b

668) Patient came after deep laceration at the anterior part of the wrist:

- a. Wrist drop
- b. Sensory loss only
- c. Claw hand
- d. Unable to do thumb opposition**

The correct answer is d

- 1- **Radial nerve injury** : wrist drop , common with humerus injury (humerus groove)
- 2- **Ulnar nerve injury** : claw hand , common with elbow injury
- 3- **Median nerve injury** : unable to do thumb opposition , common with wrist injury

669) Best way to diagnose post streptococcus glomerulonephritis (spot diagnosis):

- a) **Low C3**
- b) ?or RBC casts
- c) ?

The correct answer is a (I'm not sure)

With these MCQs , I think the correct answer is a , but most sensitive in diagnosis of post streptococcus glomerulonephritis is increase ASO titer : lumpy-bumby immunofluorescence. or (streptozyme test, which tests antibodies to ASO) (if ASO titer written with MCQs , it is correct answer .

670) COPD patient with emphysema has low oxygen prolonged chronic high CO₂, the respiratory drive is maintained in this patient by:

- a. **Hypoxemia**
- b. Hypercapnemia
- c. Patient effort voluntary
- d. ?

The correct answer is a (I'm not sure)

671) Child with ear pain with positive pump test for tympanic membrane, treatment is:

- a. **Maryngiotomy**
- b. Amoxicillin/Potassium
- ?

The correct answer is a

672) Patient has fatigue while walking last night. He is on atrovastatin for 8 months, Ciproflaxacin, Daltizem and alphaco..... the cause of this fatigue is:

- a. Daltizem and Atrovastatin
- b. **Atrovastatin and Ciprovluxacin**
- c. Atrovastatin and Alphaco
- d. ?

the correct answer is b (I'm not sure)

673) Patient with ischemic stroke present after 6 hours, the best treatment is:

- a) **ASA**
- b) TPA

- c) Clopidogril
- d) IV heparin
- e) Other anticoagulant

The correct answer is a

- 1- **TPA** : administered within 3h of symptoms onset (if no contraindication)
- 2- **ASA**: use with 48h of ischemic stroke to reduce risk of death.
- 3- **Calopidogril** : can be use in acute ischemic
- 4- **Heparin & other anticoagulant** : in patient has high risk of DVT or AF

.....

674) Patient with lateral and vertical diplobia, he can't abduct both eyes, the affected nerve is:

- a) **II**
- b) **III**
- c) **VI**
- d) **V**

I think this is diplopa because nerve 4 , but with this Q I choose c

675) Infant with heamangioma on forehead obscuring the vision, best thing to do is to remove the lesion to avoid amblyobia, after:

- a) One day
- b) One week
- c) One month
- d) 6 months
- e) One year

The correct answer is b (I'm not sure)

.....

676) Photophobia, blurred vision, keratic ?? behind cornea and cells in anterior chamber, the best treatment is :

- a) Topical antifungal

b) Topical Acyclovir

c) Antibiotic

d) ?

The correct answer is b

677) Most common medical problems faced in primary health care is:

a) Coryza

b) UTI

c) Hypertension

d) Diabetes

The correct answer is a

678) Old lady afraid of Osteoporosis, to avoid the risk, you should advise her to do:

a) Weight bearing exercise

b) ?

c) ?

d) ?

Q is not complete.

679) Obese lady with essential hypertension, lab work showed: high Na, High K, The reason for Hypertension is:

a) Obesity

b) High Na intake

c) High K intake

d) ?

The correct answer is a, more than 85% of essential hypertension with BMI > 25 .

680) Patient with eruptive purpuric rash, hepatosplenomegaly,

a) ?

- b) ?
- c) ?
- d) ?

681) Single thyroid nodule showed high iodine uptake, best treatment is:

- a) Radio Iodine 131
- b) Send home
- c) Antithyroid medication
- d) Excision if present

[The correct answer is c](#)

682) Athlete with tinea pedis best treatment is:

- a) Topical antifungal
- b) Systemic antifungal
- c) Drug starts with terbinafine
- d) ?

[The correct answer is a](#)

683) Young patient with congested nose, sinus pressure, tenderness and green nasal discharge, has been treated three times with broad spectrum antibiotics previously, what is your action?

- a) Give antibiotic
- b) Nasal corticosteroid
- c) Give anti histamine
- d) Decongestant

[The correct answer is b](#)

684) Thyrotoxicosis include all of the following, Except:

- a) Neuropathy
- b) Hyperglycemia
- c) Peripheral Proximal myopathy
- d)

Q is not complete , all MCQs are wrong , may be choice d is correct if mention .

685) Male patient has hair loss started as fronto-temporal and moving toward the vertex (top of the head) the diagnosis is:

- a) **Androgenic alopecia**
- b) Tinea Capitis
- c) ?
- d) ?

The correct answer is a

686) Young healthy male has abdominal pain after basketball. Examination fine except for Left paraumbilical tenderness, what to do:

- a) Abdominal US
- b) Flat plate graph
- c) **Send home & reassess within 48 hours**
- d) ?

The correct answer is c (I'm not sure) , confuse with choice a

687) 10 year-old boy withto tell that spinal cord length will stop after:

- a) ?
- b) ?

Length stop at L1 \ L2

688) Child with atopic dermatitis at night has stridor plus barking cough on and off from time to time, diagnosis is:

- a) BA
- b) Croup
- c) **Spasmodic Croup**
- d) ?

The correct answer is c

Spasmodic croup : recurrent sudden upper airway obstruction which present as stridor and cough . approximately 50% of children have atopic disease.

689) Sickle cell anemia patient presented with asymptomatic unilateral hip pain, most likely diagnosis is:

- a) Septic arthritis
- b) Avascular Necrosis**
- c) ?

[The correct answer is b](#)

690) Best drug to treat depression in children and adolescent is:

- a) Fluoxetine (Prozac)**
 - b) ?
-

691) Old male with neck stiffness, numbness and parasthesia in the little finger and ring finger and positive raised hand test, diagnosis is:

- a) Thoracic outlet syndrome**
- b) Impingement syndrome
- c) Ulnar artery thrombosis
- d) Do CT scan for Cervical spine

[The correct answer is a](#)

692) Patient diagnosed with obstructive jaundice best to diagnose common bile duct obstruction:

- a) ERCP**
- b) US
- c) ?

[The correct answer is a](#)

693) Endometriosis best diagnosed by

- a) US
- b) Laparoscopy**
- c) Lapratomy
- d) ?

[The correct answer is b](#)

694) Child was sick 5 days ago culture taken showed positive for meningococcal.

Patient now at home and asymptomatic your action will be:

- a) Rifampicin
- b) IM Ceftriaxone
- c) ?
- d) ?

[Q not complete \(i.m ceftriaxon single dose or oral rifampicin 2-5 days \)](#)

695) Infant with bright blood, black stool and foul smelling stool. Best way to know the diagnosis:

- a) US
- b) Radio Isotop scan
- c) Angiogram
- d) ?

[All MCQs are wrong , if stool analysis is present , it is correct.](#)

696) Primary hyperaldosteronism associated with:

- a) Hyponatremia
- b) Hypomagnesemia
- c) Hypokalemia
- d) Hyperkalemia

[The correocr answer is c](#)

697) A vaccination for pregnant lad with DT

- a) Give vaccine and delivery within 24 hrs
- b) Contraindicated in pregnancy
- c) Not contraindicated in pregnancy
- d) ?

[The correct answer is c](#)

698) A study done to assess the risk of long taking Ca in two groups the diseased group with long Ca plus control according to geographical location, site, and population. It adds (??) this type of study:

- a) Cohort
- b) Case Control (retrospective)
- c) Correlation study
- d) ?

The correct answer is a

Cross-Sectional Study:

status of individual with respect to presence and absence of both exposure and disease assessed at one point in time

case control study (retrospective) :

samples a group of people who already have a particular outcome (cases) and compares them to a similar sample group without that outcome (controls)

cohort study : (prospective, incidence , longitudinal)

subjects are sampled and as a group are classified on the basis of presence or absence of exposure to a particular risk factor

699) Define Epidemiology

- a) ? "The study of the distribution and determinants of disease prevalence in man"

700) Case Control description

- a) Start with the outcome the FU risk factors
 - b) ?
-

701) Using gastric lavage :

- a) Useless after 8 hours of ASA ingestion
- b) No benefit after 6 hours of TCA ingestion
- c) ?

The correct answer is a

702) 10 years old child with rheumatic fever treated early, no cardiac complication.

Best to advice the family to continue prophylaxis for:

- a) 1 month
- b) 3 ys
- c) 4 ys
- d) 15 ys

The correct answer is d (I'm not sure , if there is 11 years choose it)
American heart associated has recommended all patient with history rheumatic fever be placed on long term penicillin prophylactic. Duration of prophylaxis depends on presence or absent of carditis, but for children without carditis , duration minimum 5 years or at age 21, whichever is longer.

703) Picture of large neck mass only no other manifestations or organomegaly or lymphadenopathy, diagnosis is:

- a) Mononucleosis
- b) I would say **Goiter**
- c) ?
- d) Lymphoma

The correct answer is b

704) Patient with nausea, vomiting, and diarrhea developed postural hypotension.

Fluid deficit is:

- a) Intracellular
- b) **Extracellular**
- c) Interstitial

The correct answer is b

705) Cardiac syncope:

- a) Gradual onset
- b) Fast recovery
- c) Neurological sequence after
- d) ?

.....

706) Best way to decrease pain in elderly with bilateral knee pain and crepitation is:

- a) NSAID
- b) Decrease weight
- c) Exercise
- d) ?

[The correct answer is b](#), (I'm not sure)

707) Young female with whitish grey vaginal discharge KOH test ?? smell fish like
diagnosis is:

- a) Gonorrhea
- b) Bacterial Vaginosis**
- c) Trachomonous Vaginalis
- d) ?

[The correct answer is b](#)

.....

708) Old lady with osteoporosis asked for treatment for prevention:

- a) VIT. D**
- b) VIT. E
- c) Retonic Acid
- d) ?

[The correct answer is a](#)

.....

709) Young male with morning stiffness at back relieved with activity and uveitis:

- a) **Ankylosing Spondylitis**
- b) ?

.....

710) Best way to prevent infection in medical practice in pediatric

- a) Wear gloves
- b) **Wash hand**
- c) Wear mask
- d) Wear gown

[The correct answer is b](#)

.....

711) High risk for developing colon cancer in young male is:

- a) Smoking, high alcohol intake, low fat diet
- b) Smoking, low alcohol intake, high fat diet
- c) **Red meat diet, garden's disease (Gardner syndrome)**
- d) Inactivity, smoking

[The correct answer is c](#)

712) Alternative therapy for severe depression and resistance to anti-depressant medications are:

- a) SSRI
- b) TCA
- c) **ECT**

[The correct answer is c](#)

.....

713) Patient had history of pancreatic cancer on chemotherapy then improved completely, came to doctor concerning about recurrence of cancer and a history of many hospital visits. This patient has:

- a) Malingering
- b) **Hypochondriasis**
- c) Factitious
- d) Conversion

[The correct answer is b](#)

714) Patient came with neck swelling, ,moves when patient protrude his tongue.

Diagnosis is:

- a) Goiter
- b) Tyroglossus Cyst
- c) Cystic Hygroma
- d) ?

[The correct answer is b](#)

**715) Pregnant patient came with neck swelling and multiple nodular non-tender goiter
the next evaluation is:**

- a) Thyroid biopsy
- b) Give anti-thyroid medication
- c) Radiation Iodine
- d) TSH & Free T4, or just follow up

[The correct answer is d](#)

**716) Young patient with HTN came complaining of high blood pressure and red,
tender, swollen big left toe, tender swollen foot and tender whole left leg.**

Diagnosis is:

- a) Cellulitis
- b) Vasculitis
- c) Gout Arthritis
- d) ??

[The correct answer is a , because tender and swollen whole left leg.](#)

717) What is the injection that is routinely given to newborn to inhibit hemorrhage:

- a) Vit. K
- b) Vit. C
- c) Vit. D
- d) Vit. E

[The correct answer is a](#)

718) Patient with strong genetic factor for colon cancer, what is the medication that could decrease the risk of colon cancer:

- a) Folic Acid.
- b) Vit. C
- c) Vit. K or A
- d) Vit. E

The correct answer is a (folaic acid and vit. C both are prevent colon cancer , but folat reduce risk in people who genic predisposing)

719) Patient with asthma, well controlled by albutarol, came complaining of asthma symptoms not respond to albutarol, what medication could be added:

- a) Corticosteroid inhaler
- b) Long acting B-agonist
- c) Oral corticosteroid
- d) Theophylline

The correct answer is a

720) Henoch-Schölen purpura affect:

- a) Capillary
- b) Capillary and venule
- c) Arteriole, capillary and venule
- d) Artery to vein

The correct answer is c

721) Contraceptive pill that contain estrogen increase risk of:

- a) Breast Ca
- b) Ovary Ca
- c) Cervical Ca
- d) ?

The correct answer is a

722) Patient came with upper respiratory tract infection with red conjunctiva, the cause is:

- a) Viral infection
- b) Bacterial infection
- c) Fungal infection
- d) ?

[The correct answer is a](#)

723) Healthy patient with family history of DM type 2, the most factor that increase chance of DM are:

- a) HTN and Obesity
- b) Smoking and Obesity
- c) Pregnancy and HTN
- d) Pregnancy and Smoking

[The correct answer is a](#)

724) Patient complaining of back pain and hypersensitive skin of the back, on examination, patient had rashes in the back, tender, red base distributed as blunt shape on the back, diagnosis is:

- a) Herpes Zoster
- b) CMV
- c) ?
- d) ?

[The correct answer is a \(q not complete \)](#)

725) Old patient complaining of hematuria, on investigation, patient has bladder calculi, most common causative organism is:

- a) Schistosoma
- b) CMV
- c) ? virus
- d) ? virus

[The correct answer is a](#)

726) Blood culture show gram negative rod shape that grow only on charcoal free fungal organism is:

- a) Staph. Aureus
- b) Chlamydia
- c) Klebsiella
- d) Mycoplasma

All above are wrong , legionella : grame negative rod growth on charcoal agar

727) Klebesilla feacalis cause the following disease:

- a) Pneumonia
- b) ?
- c) ?
- d) ?

Enterococcus faecalis → Cause Gastroenteritis

728) Dermatomyositis came with the following symptoms:

- a) Proximal muscle weakness
- b) Proximal muscle tenderness
- c) ?
- d) ?

The correct answer is a

729) Bursitis of the elbow joint caused by:

- a) Elbow trauma
- b) Autoimmune disease
- c) Staph. Aureus
- d) ? rupture of bursa

The correct answer is a

730) Patient came with symptoms of anxiety including palpitation, agitation, and worry. The first best line for treatment is:

- a) **SSRI**
- b) **TCA**
- c) **B-blocker**
- d) **MAOI**

The correct answer is a , I'm not sure

May be the correct answer is b because there is agitation (also, side effect of SSRI)

731) Pregnant diagnosed with UTI. The safest antibiotic is:

- a) Ciprofloxacin
- b) Ampicilin
- c) Tetracycline
- d) ?

With these MCQs , the correct answer is b , but if present **nitrofurantion** is more accurate answer . UTI in pregnancy treated by : **nitrofurantion or cephalosporine** (3– 7 days) in symptomatic or asymptomatic UTI . avoid fluroroquinolone (which include : ciprofloxacin, gatifloxacin, levofloxacin, norfloxacin).

732) Patient is complaining of right side pharynx tenderness on examination patient had inflamed right tonsil and redness around tonsil with normal left tonsil. The diagnosis is:

- a) Parenchymal tonsillitis
- b) Quinse parapharyngeal abscess
- c) ?
- d) ?

The correct answer is b

733) Patient came complaining of fever, night sweating, and hemoptysis with positive PPD test. Examination was normal, CXR shows infiltrate of left apical lung but in lateral X-ray showed nothing the repeated PPD test showed normal result diagnosis is:

- a) Sarcoidosis
- b) Reactivated TB
- c) Mycoplasma infection
- d) Viral infection

The correct answer is b

734) Femal patient came with lower abdominal pain, fever on exam patient has lower abdominal tenderness and tender cervical fornix, the most appropriate way to diagnose the problem is:

- a) Laproscopy
- b) Heterosalpingography
- c) Abdominal CT
- d) Radionuclar Study

[The correct answer is a](#)

735) The best non-medical therapy is proven to be of benefit for osteoarthritis is:

- a) Muscle strength exercise
- b) Give NSAID
- c) Back slap
- d) ?

[The correct answer is a](#)

736) Hematological disease occurs in children, treated with heparin and fresh frozen plasma what is the disease:

- a) Hemophilia A
- b) Hemophilia B
- c) Von-wille brand disease
- d) DIC thrombosis

[The correct answer is d](#)

737) Child with URTI is complaining of bleeding from nose, gum and bruising the diagnosis is:

- a) Hemophilia A
- b) ITT
- c) ?
- d) ?

[The correct answer is b](#)

738) Patient came complaining of vague abdominal pain for 6 hours then shifted to right lower quadrant diagnosis is :

- a) Acute appendicitis
- b) Diverticulitis
- c) ?
- d) ?

[The correct answer is a](#)

739) Female patient is complaining of abdominal distension, fever and nausea abdominal x-ray showed (Ladder sign) management is:

- a) Colostomy
- b) Ileus treatment
- c) Rectal de-obstruction
- d) ?

[The correct answer is b \(I'm not sure because Q IS NOT COMPLETE \)](#)

740) The best stimulus for breast milk secretion is :

- a) Estrogen
- b) Breast feeding
- c) ?

[The correct answer is b](#)

741) Female patient did urine analysis shows epithelial cells in urine, it comes from:

- a) Vulva
- b) Cervix
- c) Urethra
- d) Ureter

[The correct answer is c](#)

742) All of the following are risk factors for heart disease except:

- a) High HDL
- b) Male

c) Obesity

The correct answer is a

743) The most signs and symptoms of abruption of placenta is:

- a) Vaginal bleed
- b) Fetal distress
- c) Uterus pain and back pain
- d) Abnormal uterine contraction

The correct answer is a

744) Sign of severe hypokalemia is:

- a) P-wave absence
- b) Peak T-wave
- c) Wide QRS complex
- d) Seizure

The correct answer is d , (I'm not sure , may be choice e if mention , is correct)
severe hypokalemia is defined as a level less than 2.5 mEq/L.

Severe hypokalemia is not linked with any symptoms, but may cause:

- 1- muscle
- 2- myalgia or muscle pain
- 3- disturbed heart rhythm including ectopy (disturbance of the electrical conduction system of the heart where beats arise from the wrong part of the heart muscle)
- 4- serious arrhythmias (electrical faster or slower than normal)
- 5- greater risk of hyponatremia (an electrolyte disturbance in humans when the sodium concentration in the plasma decreases below 135 mmol/L) with confusion and seizures

ECG changes in hypokalemia :

- 1-T-wave flattening

- 2-U-wave : (additional wave after the T wave)
 3-ST – segment depression

ECG changes in hyperkalemia :

- 1- peak T wave
 2- wide QRS (in severe case)
 3- PR prolong (in severe case)
 4- loss of P wave

.....

745) Child came with his father and high BMI and look older than other children with same age, on exam child has >95th percentile of weight and tall, management is:

- a) Observe and appoint
 b) Life style change
 c) Give program to decrease the weight
 d) ?

The correct answer is a

746) Pregnant on 36th week came with 7 cm cervical width at 0 station. During birth, CTG shows late deceleration, management is:

- a) Give Oxytocin
 b) O2 and change mother position
 c) Give Mg sulfate
 d) ?

The correct answer is b

Type of deceleration	etiology	management
Early	Head compression from uterine contraction (normal)	No treatment
Late	Uteroplacenta insufficiency and fetal hypoxia	<ul style="list-style-type: none"> • Place patient on side • Discontinue oxytocin. • Correct any hypotension • IV hydration. • If decelerations are associated with tachysystole consider terbutaline 0.25 mg SC • Administer O2 • If late decelerations persist for more than 30 minutes despite the above maneuvers, fetal scalp

		<p>pH is indicated.</p> <ul style="list-style-type: none"> • Scalp pH > 7.25 is reassuring, pH 7.2-7.25 may be repeated in 30 minutes. • Deliver for pH < 7.2 or minimal baseline variability with late or prolonged decelerations and inability to obtain fetal scalp pH
Variable	Umbilical cord compression	<ul style="list-style-type: none"> • Change position to where FHR pattern is most improved. Trendelenburg may be helpful. • Discontinue oxytocin. • Check for cord prolapse or imminent delivery by vaginal exam. • Consider amnioinfusion • ☑ Administer 100% O2

747) The way to determine the accuracy of occult blood test for 11,000 old patients is by measuring:

- a) Sensitivity
- b) Specificity
- c) Positive predictive value
- d) Negative predictive value

[The correct answer is a](#)

.....

748) Sick cell patient, asymptomatic with history of recurrent gall-stones and recurrent crisis the management is:

- a) Cholecystectomy
- b) Hydroxyurea

[The correct answer is a](#)

.....

749) Patient came with HTN, KUB shows small left kidney, arteriography shows renal artery stenosis, what is the next investigation:

- a) Renal biopsy

- b) Renal CT scan
- c) Renal barium
- d) Retrograde pyelography

The correct answer is

750) The way to differentiate between low iron level from iron deficiency anemia and anemia of chronic disease is:

- a) Ferritin
- b) TIBC
- c) Serum Iron
- d) Serum Transferrin

The correct answer is a

751) Patient came with hallucination and illusion the medication that should be given is:

- a) Carbamazepin
- b) ? Haloperidol
- c) ?

Q not complete, but with this scenario and MCQs , the correct answer is b

752) As doctor if you see patient and you face difficulty to get accurate information from him the best tactic to do it is:

- a) Ask direct question
- b) Ask open question
- c) Control way of discussion
- d) ?

The correct answer is a

753) (long question) patient came with MDD so during communication with patient you will find :

- a) Hypomania
- b) Late morning awake
- c) Loss of eye contact
- d) ?

[The correct answer is b](#)

754) Child patient after swimming in pool came complaining of right ear tenderness on examination patient has external auditory canal redness, tender, and discharge the management is:

- a) Antibiotics drops
- b) Systemic antibiotics
- c) Steroid drops
- d) ?

[The correct answer is a](#)

755) Child came with inflammation and infection of the ear the most complication is:

- a) Labrynthitis
- b) Meningitis
- c) Encephalitis
- d) Mastoiditis

[The correct answer is d](#)

756) Elderly patient complaining of urination during night and describe when he feel the bladder is full and need to wake up to urinate, he suddenly urinate on the bed this is:

- a) Urgency incontinence
- b) Urge incontinence
- c) Stress incontinence
- d) Flow incontinence

[The correct answer is d](#)

types	Hx of urine loss	mechanism	treatment
-------	------------------	-----------	-----------

total	Uncontrolled loss at all times and in all position	Loss of sphincter efficiency or abnormal connection b\w urinary tract and skin(fistula)	surgery
stress	After increase abdominal pressure (coughing, sneezing, lifting)	Urethral sphincter insufficiency due to laxity of pelvic floor musculature , common in multiparous women	Kegal exerciseand pessary surgery
urge	Strong, unexpected urge to void that is unrelated to position or activity	Detrusor hyperreflexia or sphincter dysfunction or neurologic disorder	Anticholinergic – medication or TCA : behavior training
overflow	Chronic urinary retention	Increase intravesical pressure that just exceed the outlet resistance , <u>allow small amount of dribble out</u>	Placement of urethra catheter , treat underlying causes

757) Newborn came with red-lump on left shoulder, it is:

- a) Hemangioma
- b) ?
- c) ?

Q is not complete

.....

758) Child came to ophthalmology clinic did cover test, during eye cover , his left eye move spontaneously to left, the most complication is:

- a) Strabismus
- b) Glaucoma
- c) Myobloma
- d) ?

The correct answer is a

.....

759) Newborn came with congenital hepatomegaly, high LFT, jaundice the most organism cause this symptoms is:

- a) Congenital TB
- b) Rubella
- c) HIV
- d) CMV

[The correct answer is d](#)

760) Gross motor assessment at age of 6 months to be asked is:

- a) Sitting without support
- b) Standing
- c) Role from prone to supine position
- d) Role from supine to prone position

[The correct answer is a](#)

761) Female child came with precocious puberty the most cause is:

- a) Idiopathic
- b) Adrenal tumor
- c) Brain tumor
- d) ? ovarian tumor

[The correct answer is a](#)

762) Hemorrhoid usually occurs in:

- a) Pregnancy and portal HTN
- b) ?
- c) ?
- d) ?

[Q is not complete](#)

Most common causes of hemorrhoid : increase straining (constipation) ,
portal HTN , increase abdominal pressure (chronic cough , pelvic tumor) ,
obesity , pregnancy , smoking

763) The immediate urgent referral of child that take

- a) **10 pills contraceptive**
- b) **10 pills antibiotics?**
- c) **75 mg ?**

?????

764) Most unwanted side effect of anti-cholinergic drugs is :

- a) **Constipation**
- b) **?**
- c) **?**

more than 50% of patients taking anticholinergic have side effects : dry mouth, blurry vision, constipation and urinary retention.

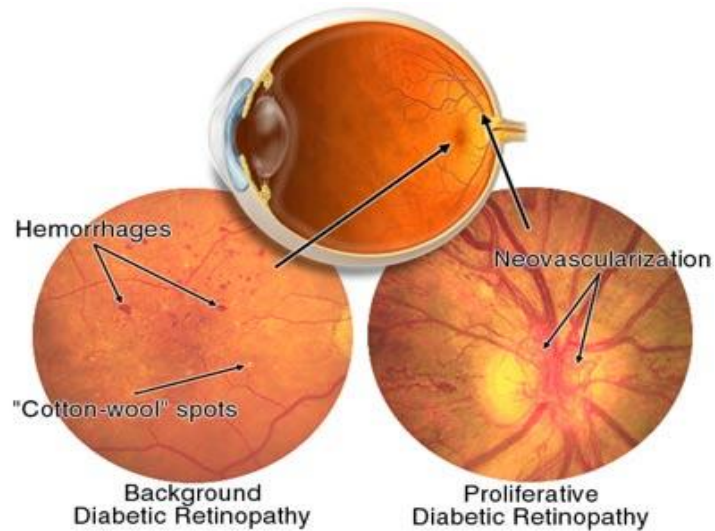
765) Patient with DM II with good vision, to prevent eye disease (Retinal back ground) to develop is to avoid:

- a) **HTN, Smoking**
- b) **Obesity, Smoking**
- c) **HTN, Obesity**
- d) **?**

The correct answer is c

The risk factors that increase diabetic retinopathy background are:

- 1- **HTN**
- 2- **Poor glucose control or long case D.M**
- 3- **Raised level of fat (cholesterol)**
- 4- **Renal disease**
- 5- **Pregnancy (but not in diabetes caused by pregnancy)**



766) Best medication to be given for GDM (gestational) is:

- a) Insulin
- b) Metformin
- c) ?

[The correct answer is a](#)

767) A child is complaining of severe headache which is unilateral, throbbing and aggravated by light, diagnosis is:

- a) Migraine
- b) Cluster Headache
- c) Stress Headache
- d) ?

[The correct answer is a](#)

768) The most important factor for smoker to quit is :

- a) Patient desire
- b) Give nicotine pills
- c) Give programmed plan
- d) Change life style

The correct answer is a

769) Patient is complaining of irritation, tachycardia, night sweating, labs done showed

TSH: Normal, T4: High, diagnosis is:

- a) Grave's disease
- b) Secondary Hypothyroidism
- c) Hashimoto's thyroiditis
- d) ?

All MCQs are wrong , choice d may be correct if mention

Normal TSH and increase T4 : in **thyroid tropin secretary pitutay adenoma = thyroid resistance** .

770) The most active form is:

- a) T4
- b) T3
- c) TSH
- d) TRH

The correct answer is b

771) Middle age man found to have heaviness in his groin. On physical examination there was swelling just above his testis which apparent with valsalva maneuver.

What is the diagnosis:

- a) Direct inguinal hernia
- b) Indirect inguinal hernia
- c) Femoral Hernia
- d) Testicular mass
- e) Hydrocele
- f) Varicocele

The correct answer is b

772) Gardener has recurrent conjunctivitis. He can't avoid exposure to environment. In order to decrease the symptoms in the evening, GP should advise him to:

- a) Cold compression

- b) Eye irrigation with Vinegar Solution
- c) Contact lenses
- d) Antihistamines

[The correct answer is d](#)

773) 48 year-old male complaining of lower back pain with morning stiffness for 30 minutes only. On exam he was having spasm centrally on the lower back. What is the appropriate management :

- a) Epidural steroids injection
- b) Back brace
- c) Facet lysis
- d) Physiotherapy

[The correct answer is d](#)

774) 41 weeks pregnant lady last biophysical profile showed oligohydroamnios. She has no complaints except mild HTN. What is the appropriate management :

- a) Wait
- b) Induce labor post 42 wks
- c) Induce labor
- d) Do biophysical profile twice weekly

[The correct answer is c](#)

775) Full term wide pelvis lady, on delivery station +2, vertex, CTG showed late deceleration, the most appropriate management:

- a) C/S
- b) Suction
- c) Forceps Delivery
- d) Spontaneous Delivery

[The correct answer is c \(I'm not sure \)](#)

776) Recent study revealed that anti psychotic meds cause the following complication:

- a. wt gain
- b. alopecia
- c. cirrhosis

the correct answer is a

777) complication of rapid correction of hypernatremia :

a. brain edema

in hypernatremia : gradually correction to prevent cerebral edema

in hyponatremia : gradually correction to prevent ,myelinolysis (include paraparesis \ quadriparesis , dysarthria and coma

778) prophylaxis of cholera :

Cholera is an infection of the small intestine that is caused by the bacterium ***Vibrio cholerae***. The main symptoms are profuse watery diarrhea (rice-watery diarrhea) vomiting and dehydration . infection by fecal-oral rout .

treatment : 1- rehydration , 2-antibiotic : young & adult : doxycycline or tetracycline , for children : SMX-TMP , for pregnant : furazolidone .

prphylaxis : good hygiene and sanitation and oral vaccine , in epidemic public : mass single dose of vaccine and tetracycline.

778)which one of the anti TB medications cause tinnitus, imbalance..

a. streptomycin

b. isoniazide

c. pyrizinamide

the correct answer is a , sterptomycine : cause 8th nerve damage

779) the following combination drug should be avoided :

a. levodopa & digoxin

Q is not complete

780) young male had pharyngitis, then cough, fever, most likely org

- a. staph aureus**
- b. strept pneumonia**

[the correct answer is b](#)

781) most effective measure to prevent spread of infection among health care workers & pts in a nursery:

- a. wash hand before and after examining each pt**
- b. wear gown and gloves before entering the nursery**
- c. wear shoe cover**

[the correct answer is a](#)

782) 27 yrs old female with perianal pain for 4 days tender erythematous fluctuating

- a. Abx**
- b. local CS**
- c. Sitz bath**
- e. evac & drain**

[the correct answer is e](#)

783) female pt developed extreme fear from zoo, park, sporting events, the fear prevented her from going out:

- a. agoraphobia**
- b. social phobia**

c. schizophrenia

the correct answer is a , (agoraphobia : fear going out from the home)

784)child starts to smile:

a. at birth

b. 2month

c. 1month

The correct answer is b

785)child recognize 4 colors, 5 words, hops on one foot, consistent with which age:

a. 12 mons

b. 24 mons

c. 36 mons

d. 18 mons

the correct answer is c

786)pt with hx of 5 yrs HTN on thiazide, came to ER midnight screaming holding his Lt foot, o/e pt afebrile,Lt foot tender erythema, swollen big toe most tender and painful, no other joint involvement

a. cellulitis

b. gouty arthritis

c. septic arthritis

the correct answer is b

787)23 yrs old married for 3 mons, c/o not getting pregnant, they have intercourse 3-4 times/week, normal gynecologic hx, husband 25 yrs old healthy wt would you advice:

a. cont. trying

- b. obtain sperm analysis
- c. study of tubes patency

[the correct answer is a](#)

788)pt with AF what is the most common complication:

- a. cerebrovascular events
- b. v.tach
- c. AMI
- d. v.fib

[the correct answer is a](#)

789)case scenario : oral+genital ulcer +arthritis

- a. behcet disease
- b. syphilis
- c.herpes simplex

[the correct answer is a](#)

790) 20 yrs old lady, pregnant, exposed to rubella virus since 3 days , never was vaccinated against rubella mumps or measles , what's the best thing to do:

- a. give IG
- b. vaccine
- c. do nothing
- d. terminate the pregnancy

[the correct answer is c , only supportive . \(100 % correct ☺ \)](#)

790)which of the following not compatible with head engagement:

- a. vertex at zero station**
- b. crowning of the head**
- c. 3/5 head felt in the abdomen**
- d. BPD at ischial spines**

the correct answer is c , **When the fetal head is engaged, 2/5 or less of the head is palpable above the pelvic**

791)58 yrs old female, known case of osteopenia, she's asking you abt the best way to prevent compression vertebral fracture, what would you advice her:

- a. avoid obesity**
- b. vit.D daily**
- c. wt bearing exercise**

the correct answer is c , confuse with choice b

mild osteopenia (T score -1 to -2): life style modification (stop smoking) , daily calcium intak (1500 mg daily) , exercise , and reassessed after 3 – 5 years .

severe osteopenia (T score -2 to – 2.5) and osteoporosis (T score > 2.5) : same mild plus pharmacological .

792) Mother complains of sharp pain on radial styloid when carrying her baby. The pain increase with extension of the thumb against resistance, Finkelstein test was positive, Dx :

- a. Osteoarthritis of radial styloid
- b. De Quervain Tenosynovitis

[the correct answer is b](#)

793) 1st line in Trigeminal Neuralgia management:

- a. Carbamazepine

794) Contraindicated in acute glaucoma management:

- a. Pilocarpine
- b. Timolol
- c. B-blockers, CA inhibitors, NSAID, Mannitol
- d. ?

[All of MCQs can be use in acute glaucoma . may be choice d is correct if mention.](#)

795) True about systolic hypertension:

- a. could be caused by mitral Regurg
- b. More serious than diastolic hypertension
- c. systolic >140 and diastolic <90
- d. ?

[the correct answer is c](#)

796) Pregnant 38GA, presented in labor, dilated cervix, station 42, late deceleration on CTG, management:

- a. continuo spontaneous labor

- b. Forcep delevary
- c. Vacuum Delevary
- d. CS

The correct answer is a (I'm not sure)

797) Pt, febrile, tender prostate on PR:

- a-Acute Prostitis

798) Proven to prevent some cancers:

- a. Ca
- b. Folic Acid
- c. Vit.D

[the correct answer is c](#)

799) Patient with cont. Murmur:

- a. PDA
- b. Coarctation of Aorta

[the correct answer is a](#)

800) Old man, post OR, Complains of unilateral face swelling:

- a. Sjarjan syndrome
- b. Sarcoidosis
- c. Salivary gland tumor
- d. Salivary gland stone

[the correct answer is d](#)

801) At what level LP done:

- a. L2-L3
- b. L3-L4

c. L5-S1

[The correct answer is b](#)

802) 2 months old with scaling lesion on scalp and forehead, Dx:

- a. Seborrheic Dermatitis
- b. Erythema multiforme

[the correct answer is a](#)

803) Pt have high Blood Pressure on multiple visits, so he was diagnosed with hypertension, what is the Pathophysiology:

- a. increased peripheral resistance
- b. increased salt and water retention

[the correct answer is a](#)

804) 13 years old with hx of pneumonia and managed with abx 2 weeks back, now he came with diarrhea, abdominal pain, and +ve WBC in stool, the causative organism is:

- a. Clostridium difficile
-

805) Best Manag. Of Clostr. Difficile is:

- a. Metronidazole
- b. Doxycycline

[the correct answer is a](#)

806) Prophylaxis of arrhythmia post MI :

- a. Quinidine
- b. Quinine
- c. Lidocaine
- d. Procainamide

[the correct answer is c , if b-blocker is present choose it](#)

807) Chronic Diarrhea is a feature of:

- a. Hypernatremia

- b. HyperCalcemia
- c. HypoMagneemia
- d. Metabolic Alkalosis

[The correct answer is d](#)

808) Pt with have Polyuria and thirst, he had Hx of bipolar on lithium, Dx:

- a. Nephrogenic Diabetes Insipidus
- b. central Diabetes Insipidus

[the correct answer is a](#)

809) In city with population of 15000 people & 105 birth /yr , 4 are still birth ,3 died within months ,2 died before their 1st birthday , with 750 p come out & 250 come in what is the birth mortality rate in this city :

- a. 4
- b. 6
- c. 8
- d. 9

Q not complete (I didn't find anything about birth mortality rate)

810) Female with recently inserted IUCD coming with watery brownish vaginal discharge & abdominal pain what is the most likely Dx :

- a. Uterine rupture
- b. Ovarian torsion
- c. Bacterial vaginosis
- d. Ectopic pregnancy

[The correct answer is d](#)

811) 38 y/o male calling you complaining of fear from going outside & fear from seeing the front door & don't sit in the room containing the front door what is most likely Dx:

- a. Depression
- b. Agoraphobia
- c. Malingering
- d. Anti-social personality

[The correct answer is b](#)

812) 60 y/o male known to have (BPH) digital rectal examination shows soft prostate with multiple nodularity & no hard masses , the pt request for (PSA) for screening for prostatic ca what will you do :

- a. Sit with the pt to discuss the cons & pros in PSA test
- b. Do trans-rectal US because it is better than PSA in detection
- c. Do multiple biopsies for different sites to detect prostatic ca
- d.

[The correct answer is a](#)

813) What is the most effective ttt for rosacea :

- a. Clindamycine
- b. Erythromycin
- c. Topical steroids
- d.

Q is not clear or not complete. (if mention tetracycline choose it)

Treatment of Rosacea : Oral tetracyclines & topical metronidazole or topical erythromycin or topical clindamycin . **for severe case :** isotretinoin . **surgical treatment for rhinophyma .**

814) 7 y/o child coming with SOB and wheezing he was sitting in bed , leaning forward , with drooling & stridor what is Dx :

- a- Epiglottitis
- b- Bronchial asthma
- c-
- d-

[The correct answer is a](#)

815) 10 y/o child brought by his parents because they were concerned about his weight , he eats a lot of fast food and French fries , your main concern to manage this pt is :

- a- His parents concerned about his weight**
- b- His BMI > 33**
- c- Family Hx of heart disease**
- d- Eating habit (fast food , French fries)**

816) What is an absolute contraindication of OCP :

- a. Hx of previous DVT**
- b. Ovarian ca**
- c. Breast ca**
- d.**

The correct answer is a , both hx of DVT and breast cancer are absolute contraindication , but in hx DVT is more accurate

817) OCP is proven to :

- a. Decrease ovarian ca**
- b. Decrease endometrial ca**
- c. Increase breast ca**
- d. Increase risk of ectopic pregnancy**

The correct answer is c

818) Baby born & discharge with his mother , 3 weeks later he started to develop difficulty in breathing & become cyanotic what is most likely DX :

- a- VCD**
- b- Hypoplastic Lt ventricle**
- c- Coarctation of aorta**
- d- Subaortic hypertrophy**

The correct answer is b

819) 60 y/o male Dx to have acute pancreatitis (there was values for ranson criteria that I couldn't memorize) what is the appropriate nutrition :

- a- TPN
- b- Regular diet with low sugar
- c- High protein ,high ca , low sugar
- d- Naso-jejunal tube

[The correct answer is d](#)

820) 15 y/o boy brought by his mother with lab values shows microcytic hypochromic anemia what is most likely Dx :

- a- Thalassemia
- b- IDA (iron deficiency anemia)
- c- SCD
- d-

[The correct answer is b](#)

821) Female with Hx of lt flank pain radiating to groin , symptoms of UTI & N+V what is DX:

- a- Appendicitis
- b- Diverticulitis
- c- Renal colic
- d-

[The correct answer is c](#)

822) Old pt with neck swelling , nodular ,disfiguring , with Hx of muscle weakness , cold intolerance , hoarseness , what is your management :

- a- Levothyroxine
- b- Carbamazole
- c- Thyroid lobectomy
- d- Radio-active iodine

[The correct answer is a](#)

823) Pregnant woman with symptoms of hyperthyroidism , TSH low :

- a- Propylthiouracil
- b- Radio-active iodine
- c- Partial thyroidectomy

d-

[The correct answer is a](#)

824) Pt with thyroid mass , firm ,2x2 cm what is most appropriate for Dx :

- a- Neck US
- b- FNA
- c- Neck CT
- d- Surgery

[The correct answer is b](#)

825) 56 y/o female complaining of back pain , her mother suffer from vertebral compression Fx , investigation shows early osteoporosis what is the best ttt :

- a- Advice with exercise
- b- Vit D , ca supplement ,
- c-
- d-

[The correct answer is b](#)

826) What is the most common non-traumatic Fx caused by osteoporosis :

- a- Colle's Fx
- b- Femoral Fx
- c- Vertebral compression Fx

[The correct answer is c](#) , because most common non traumatic .

827) 4 or 5 (not sure) brought by his parents with weight > 95th percentile , height < 5th percentile & bowing of both legs what is the appropriate management :

- a- Liver & thyroid function tests
- b- Lower limb X-ray
- c- Pelvis X-ray
- d- Thyroid or (liver not sure) function test

[The correct answer is a](#)

828) At which stage separation of chromatoids occur :

- a- Metaphase
- b- Telophase

c-

d-

The correct answer is a

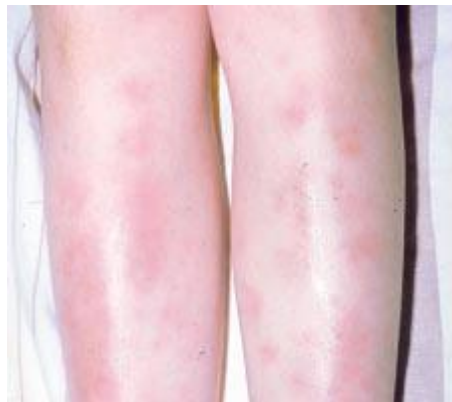829) Elderly pt with DM2 , HTN , smoker , sedentary lifestyle , investigation low HDL, high LDL , (المهم أن كل المآسي فيه) which of what will be effective in this pt :

- a- Level of HDL , smoking , obesity
- b- Triglyceride level ,
- c-
- d-(all were long sorry)

MCQs are not complete.

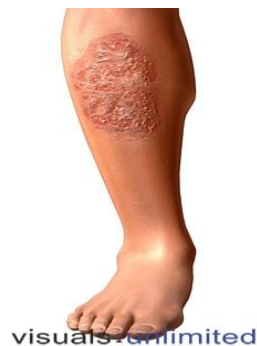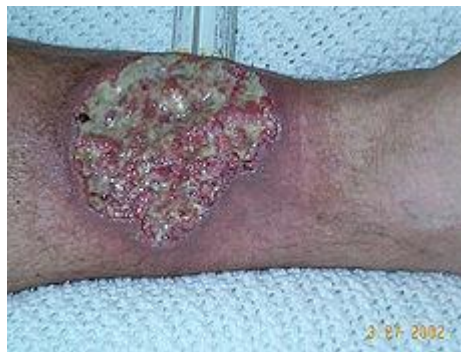830) pt known case of ulcerative colitis with erythematous rash in lower limb what is most likely DX:

- a- erythema nodosum



831) Pt known to have ulcerative colitis coming with skin lesion around Tibia which is with irregular margins what is most likely Dx:

- a- Pyoderma gangrenosum



.....
832) Young pt victim of RTA coming with SOB (or not breathing not sure) absent of breath sound & chest movement in RT side but resonance in percussion what is your next step :

- a- Do stat chest X-ray**
- b- Emergency surgery**
- c-**
- d-**

[Needle aspiration then chest tube](#)

.....
833) Psychiatric pt non-compliance to his medication what is the ttt :

- a- Given IM**
- b- given IV**
- c-oral**
- d-oral**

Q is not complete

.....
834) Which psychiatric disease is treated with electroconvulsive therapy :

- a- Paranoia**
- b-**

[The correct answer is : Major depression](#)

835) Pt with bilateral eye discharge , watery , red eyes, corneal ulceration what is the most common cause :

- a- Dust & pollen**
- b- Hypertension &**
- c- Ultra-violet light & stress**
- d-**

[The correct answer is a](#)

.....
836) 4 y/o baby fell down his mother pulled him by his arm & since then he kept his arm in pronation position what is your management:

- a- Splint**
- b- Do x-ray for the arm before any intervention**
- c- Orthopedic surgery**

d-

The correct answer is b

838) diabetic pt on medication found un conscious his blood suger was 60 what is the most common to cause this problem:

- a- Sufonylurease
- b- Bigunides
- c-

The correct answer is a

839) what is most sensitive indicator for factitious fever :

- a- Pulse rate
- b-
- c-

Factitious fever: Fever produced artificially by a patient. This is done by artificially heating the thermometer or by self-administered pyrogenic substances. An artificial fever may be suspected if the pulse rate is much less than expected for the degree of fever noted. This diagnosis should be considered in all patients in whom there is no other plausible explanation for the fever. Patients who pretend to have fevers may have serious psychiatric problems.

840) young male (I think he was a student) with headache involving the whole head & bilateral eye glob that increase with stress what is most likely DX:

- a- Tension headache
- b- Migraine
- c-
- d-

Q not cmplete

841) pt turns to be erratic , for 4 month he said that's people in TV knows what people are thinking about , in last 2 month he claim that he has special power that no one has what is the most likely DX :

- a- Uni-polar depression

- b- Bipolar Mania
- c- SCZ
- d-

[The correct answer is c](#)

842) common site of anal fissure is :

- a- Anterior
- b- Posterior
- c- Lateral
- d-

[The correct answer is : b](#)

843) common site of hernia sac in relation to the cord content :

- a- Antro-lateral
- b- Medial
- c- Anywhere
- d- Posterior

[The correct answer is a](#)

844) what a 4 years child can do :

- a- Draw square & triangle
- b- Say complete sentence
- c- Tie his shoes
- d-

[The correct answer is a](#)

845) You received a call from a father how has a son diagnosed recently with DM-I for six months, he said that he found his son lying down unconscious in his bedroom, What you will tell him if he is seeking for advise:

- a. Bring him as soon as possible to ER
- b. Call the ambulance

- c. Give him his usual dose of insulin
- d. Give him IM Glucagone
- e. Give him Sugar in Fluid per oral

The correct answer is e

846) factor which determine recurrence of breast cancer :

- a- Site & size of breast mass
- b- No of lymph nodes
- c- Positive estrogen receptor
- d- Positive progesterone receptor

The correct answer is b

847) teacher in school presented with 3 days Hx of jaundice (they wrote it ictric as if it will a differacne) & abdominal pain , N+V , 4 of school student had the same illness in lab what is true regarding this pt :

- a- Positive for hepatitis A IgG
- b- Positive hepatitis A IgM
- c- Positive hepatitis B core
- d- Positive hepatitis B c anti-body

The correct answer is b

848) regarding weight gain in pregnancy what is true :

- a- Pregnant woman should consume an average calorie 300-500 per day
- b- Regardless her BMI or body weight she should gain from 1.5 – 3 lb which represent the baby's growth
- c-
- d-

Q is not complete

Weight gain during pregnancy :

- 100 – 300 Kcal / day , 500 Kcal / day in breastfeeding
- Wt. gain : 1 – 1.5 kg / month , 11 – 16 kg gain during pregnancy.

(for change from lb to Kg : divided by 2.2)

849) what condition is an absolute contraindication of lactation :

- a- Mother with open pulmonary TB for 3 month
- b- Herpes zoster in T10 dermatome
- c- Asymptomatic HIV
- d-

[The correct answer is c](#)

850) what is most sensitive for DX of duodenal ulcer :

- a- Epigastric pain starting 30-60 min after the meal
- b- Epigastric pain starting immediately after a meal
- c- Increasing of pain when lying supine
- d- Pain radiating to the back

[The correct answer is d](#)

851) female at 40 yr with BMI >28 what is your management :

- a- Reduce calorie in take to 800 /day
- b- In general reduce calorie intake
- c-
- d-

[Q is not complete, but with these MCQs , the correct answer is b](#)

852) 70 y/o female say that she play puzzle but for a short period she can't play because as she develop headache when playing what u will exam for

- a. astigmatism
- b. glaucoma

[the correct answer is a](#)

852) prophylaxis for meningitis ttt contact

- a. cimitidine
- b. rifampicin

[the correct answer is b](#)

853) rheumatic fever pt has streptococcal pharyngitis risk to develop another attack

- a. times more than normal
- b. 100%
- c. 50%

[the correct answer is c](#)

854) child with unilateral nasal obstruct with bad odor

- a. unilateral adenoid hypertrophy
- b. FB

[the correct answer is b](#)

855) PT. do colectomy for colon cancer routine follow up every

- a. 6 months
- b. 3 months
- c. 9 months
- d. 1 years

[the correct answer is d](#)

856) for patient with osteoarthritis , what is your initial action :

- a. Intraarticular corticosteroid
- b. Quadriceps strengthening exercise
- c. Climb stairs exercise

[The correct answer is b](#)

857) 70-y old female patient with osteoporosis , what is her T score :

- a. (-2.5)
- b. (-1)

- c. (1)
- d. (2)

The correct answer is a

858) diabetic patient , diagnosed 2 weeks back came to your clinic at scheduled appointment supposed to be at 10:00 AM but because you were having another complicated case , he had to wait for more than an hour , and he was extremely angry , what u will do :

- a. be empathetic as this anger is mostly because of the new morbidity diagnosed at this patient**
- b. you start your talk with him by saying “I was having a hard case “**
- c. Don’t say anything regarding being late unless he brings it up**
- d. you star YOUR TALK WITH HIM BY SAYINH “you seem furious”**

859) 1st step in epidemic study is :

- a. verifying diagnosis**

Q is not complete

860) Randomized control trials become stronger if :

- a. you follow more than 50% of those in the study**
- b. systematic assignment predictability by participants**

Q is not complete , but with these MCQs , the correct answer is b

861) child with multiple painful swellings on the dorsum of hands , feet , fingers and toes ,his CBC showed Hb =7,RBC’s on peripheral smear are crescent shaped , what is your long-term care :

- a. corticosteroids**

b. penicillin V

c. antihistaminic

the correct answer is b , this pt. is sickle cell anemia

862) 54 y old patient , farmer , coming complaining of dry eye , he is smoker for 20 years and smokes 2 packs/ day , your recommendation :

a. advise him to exercise

b. stop smoking

c. wear sunscreen

The correct answer is b , smoking increase risk of dry eye (international study)

863) patient is wearing contact lenses for vision correction since ten years , now coming c/o excessive tearing when exposed to bright light , what will be your advice to him :

a. wear hat

b. wear sunglasses

c. remove the lenses at night

d. saline eye dros 4 times / day

The correct answer is d (I'm not sure)

864) management of mild epistaxis :

a. pinching the fleshy part of nose while telting head foreword

865) most common site of malignancy in paranasal sinuses :

a. Maxillary sinus (correct)

866) patient with hypertension , what is the best non-pharmacological method to lower the elevated blood pressure :

[a. weight reduction \(correct \)](#)

867) newly diagnosed patient with hyper tension having Na=147 , K=3 , what is the most likely cause of his secondary hypertension :

[a. hyperaldosteronism \(correct \)](#)

868) 50 year old patient , diagnosed with hypertension , he is used to drink one glass of wine every day , he is also used to get high Na and high K intake , his BMI is 30kg/m , what is the strongest risk factor for having hypertension in this patient :

- a. wine
- b. high Na intake
- c. high K intake
- d. BMI=30

[the correct answer is d , \(I'm not sure \)](#)

869) all of the following tests are necessary to be done before initiating lithium except:

[a. liver function tests](#)

870) in dementia , best drug to use :

- a. haloperidol
- b. galantamine

[the correct answer is b](#)

treatment of dementia is cholinesterase inhibitor (galantamine, donepezil, rivastigmine, and tracing)

871) most important point to predict a prognosis of SLE patient : ??

- a. degree of renal involvement
- b. sex of the patient
- c. leucocyte count

the correct answer is a

872) what is the antibiotic that you will give if you will do appendectomy :

- a. doxycycline
- b. ceftriaxone
- c. metronidazole
- d. cefuroxime

The correct answer is d

873) most common site for ectopic pregnancy :

- a. fallopian tubes
-

874) child with low grade fever , rash , pharyngitis , and tender splenomegally , +ve EBV , Dx :

- a. infectious mononeucleosis
-

875) best early sign to detect tension pneumothorax :

- a. tracheal shift
- b. distended neck veins
- c. hypotension

the correct answer is b , I'm not sure , I think tracheal shift is the late sign .

876) First sign of magnesium sulfate toxicity is :

- a. Loss of deep tendon reflex

877) Patient with mushroom toxicity will present with

- a. Constipation
- b. Hallucination
- c. Anhydrosis

the correct answer is b

878) Child ate overdose of iron , best immediate management

- a. Gastric lavage
- b. Induce vomiting manually
- c. Emetic drugs
- d. Ipecac

the correct answer is a

879) Status epilepticus is :

- a. Continuous seizure activity more than 30 min without regaining consciousness

880) First sign of increased ICP is :

- a. contralateral papillary dilatation
- b. Ipsilateral papillary dilatation
- c. Decrease level of consciousness

[the correct answer is c](#)

880) Patient with history of head trauma unable to move the fork to his mouth , where is the lesion:

- a. cerebellum
- b. frontal lobe
- c. temporal

[the correct answer is a](#)

881) Patient with lumbar canal stenosis , I forget the presentation , what is the ttt:

- a. Physiotherapy
- b. Lumbar dicsectomy

[Q IS NOT COMPLETE](#)

[Mild to moderate : NSAID + physiotherapy](#)

[Advance : epidural corticosteroid](#)

[Refractory : surgical laminectomy](#)

882) Most common cause of otorrhea :

- a. Csf leak
- b. Acute otitis media
- c. Cerumen leak

[The correct answer is b](#)

883) Most common symptoem of acute otitis media :

- a. Pain
- b. Discharge

- c. Tinnitus
- d. Vertigo

The correct answer is a

884) 12 yo boy is mocked at school because he is obese , ate a lot of pill to sleep and never wake up again , best management is :

- a. Refer to mental professional**
 - b. Tell him that most kid grow out before they grow up**
 - c. Advice healthy food**
-

885) 12 yo boy brought by his parent for routine evaluation , his is obese but otherwise healthy , his parents want to measure his cholesterol level , what is the best indicator of measuring this child cholesterol :

- a. His parent desire**
- b. Family hx of early cva**
- c. High bmi**

The correct answer is b

886) Diabetic pt. have neovasclarization and vetrous hemorrhage , next step :

- a. Refer to ophthalmologist**
-

887) Histopatholgy of resected inflamed appendix will show :

- a. Neutrophil in muscular wall**
- b. Lymphoid hyperplasia with multineucleated gaint cel**

The correct answer is a

888) A child had bee bite presented after 18 hour with left arm erythema and itching and.... Long scenario , what to do:

- a. Antihistaminic
- b. Oral steroid
- c. Subcutaneous epinephrine

[The correct answer is a](#)

889) Old man with urinary incontinence , palpable bladder after voiding , urgency and sense of incomplete voiding dx;

- a. Stress incontinence
- b. Overflow
- c. Reflex

[The correct answer is b](#)

890) Ttt of scabies :

- a. [Permethrin](#)

891) Picture , hyperkeratotic , scaly lesion over the extensor surface of knee and elbow , what to do to avoid exacerbation :

- a. Steroid
- b. Avoid sun exposure
- c. Avoid trauma

[The correct answer is a](#)

892) Which is true about allopurinol :

- a. Good if given during acute gout
- b. Uricosuric
- c. Reduce the chance of uric acid stone

d. Can be antagonized by salicylate

The correct answer is c

893) man walking in street and saying bad words to stranger, he is not aware of his condition, what is the description :

- a. flight of idea
 - b. insertion of idea
 - c. loosening of association
-

894) which of the following suggest that thyroid nodule is benign rather than malignant:

- a. history of childhood head and neck radiation
- b. hard consistency
- c. lymphadenopathy
- d. presence of multiple nodules

the correct answer is d

thyroid cancer : (cold and solid nodule)

895) child presented after sting bite with abd pain, arthralgia, lower extremity and buttock rash, normal RFT, +ve fecal occult stool, dx :

- a. HSP
- b. Lyme disease

The correct answer is a

896) best indicator for labor progress is :

- a. frequency of contractions
- b. strength of contractions
- c. descent of the presenting part

[the correct answer is c](#)

897) lactating mother is taking Phenobarbital for seizure prophylaxis, what to advise her :

- a. stop breast feeding immediately
- b. breast feed after taking the pill by 8 hour
- c. start weaning
- d. does not matter

[the correct answer is a](#)

898) best single way to reduce high blood pressure is :

- a. smoke cessation
- b. decrease lipid level
- c. reduce weight

[the correct answer is c](#)

899) drug of choice for supraventricular tachycardia is :

- a. adenosine

900) patient with blood group A had blood transfusion group B, the best statement that describe the result is :

- a. type IV hypersensitivity
- b. inflammatory reaction
- c.

[The correct answer is : It is type 2 hypersensitivity](#)

901) a nurse gave blood transfusion through CVP, 2 hours later the patient is comatose and unresponsive, dx :

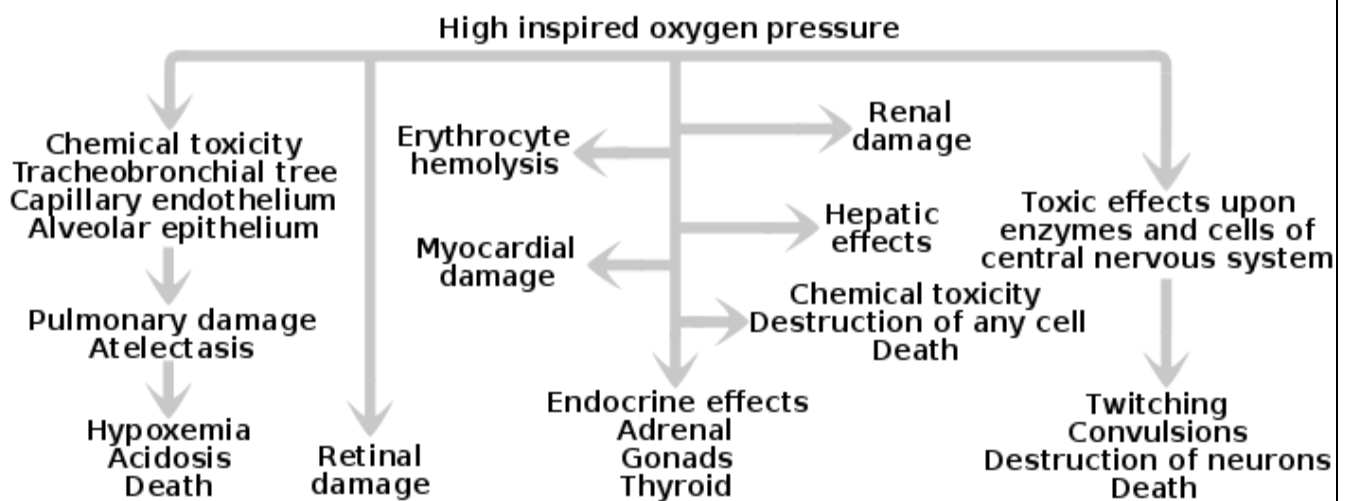
- a. Septic shock
- b. Blood group mismatch

[The correct answer is a \(I'm not sure \)](#)

902) 100% O₂ given for prolonged periods can cause all except:

- a. Retrosternal Pain
- b. Seizures
- c. Depression
- d. Ocular Toxicity
- e. ???

The correct answer is c (I'm not sure because choice e is not mention)



903) Organophosphorus poisoning, what is the antidote?

- a. Atropine
- b. Physostigmine
- c. Neostigmine
- d. Pilocarpine
- e. Endrophonium

The correct answer is a

904) Which of the following pulse character goes with the disease?

- a. Collapsing pulse → Severe anemia
- b. Pulsus Alternans → Premature ventricular complexes
- c. Slow rising Pulse → Mitral stenosis
- d. Pulsus Bisferens → Mitral Regurgitation

e. Pulsus paradoxus → I think Aortic stenosis or regurgitation

The correct answer is a

PLUSE	DEFINITION	CAUSES
Collapsing pulse	Pulse with fast upstroke and fast downstroke	1- Sever anemia 2- Aortic regurge 3- Thyrotoxicosis
Pulse alternans	Altrnans weak and strong pulse	1- LV dysfunction
Pulsus paradoxus	Decline systolic more than 10 mm Hg during inspiration	1- Cardiac tamponade 2- Asthma & COPD
Pulsus parvus et tardus	Weak and delayed pulse	1- Aortic stenosis
Slow rising pulse	Slow upstroke pulse	1- Aortic stenosis
Pulsus bisferiens	pulse characterized by two strong systolic peaks separated by a midsystolic dip	1- Aortic reguirge 2- AR + AS

905) Entamoeba histolytica cysts are destroyed best by:

- a. Boiling
- b. Iodine added to water
- c. Chlorine added to water
- d. Freezing

The correct answer is a

.....
906) A scenario about an old male with symptoms suggesting parkinsonism such as difficulty walking, resting tremors and rigidity in addition to hypotension. Then he asks about what is the most common presenting symptom of this disease

- a. Rigidity
- b. Tremors
- c. Unsteady Gait
- d. Hypotension

e. ???

[The correct answer is b](#)

907) Regarding postpartum Psychosis:

- a. Recurrences are common in subsequent pregnancies
- b. It often progresses to frank schizophrenia
- c. It has good prognosis
- d. It has insidious onset
- e. It usually develops around the 3rd week postpartum

[The correct answer is a](#)

908) A pregnant female develops lesions on the vulva and vagina and she was diagnosed as genital herpes, what should be included in her future health care?

- a. Cesarean section should be done if the lesions did not disappear before 2 weeks of delivery date
- b. Oral acyclovir to treat herpes
- c. Termination of pregnancy because of the risk of fetal malformations
- d. Avoidance of sexual intercourse for 1 month after the healing of the lesions
- e. ?????

[The correct answer is b](#)

HSV in pregnant treated by : oral acyclovir 400 mg TID for 5-7 days . if HSV was present at time of labor : c – section

909) A picture of 2 warts in the index finger.

Diagnosis is → Viral Warts

910) What is the most common sequelae of acute pancreatitis ?

- a. Abscess
- b. Pseudocyst
- c. Bowel obstruction

[The correct answer is b](#)

Most common complication of acute pancreatitis: pancreatic pseudocyst and fistula formation

911) An old patient with history of cerebrovascular disease & Ischemic heart disease, presents with a pattern of breathing described as: A period of apnea followed by slow breathing which accelerates & becomes rapid with hyperpnea & tachycardia then apnea again. What is this type of breathing?

- a. Hippocrates
- b. Chyene-stokes breathing**
- c. Kussmaul breathing
- d. One type beginning with O letter and contains 3 letters only
- e. ????

The correct answer is b

1- Chyene-stokes respiration : rapid deep breathing phase followed by period of apnea , present with heart failure , stroke, brain trauma , also can be with sleep or high altitude

2-kusmmaul's breathing : rapid and deep breathing . present with metabolic acidosis particularly in diabetic ketoacidosis

912) A patient with mixed 1st & 2nd degree burns in head & neck region, what is the most appropriate management?

- a. Apply silver sulfadiazine and cream to all burned areas, cover them and admit to hospital
- b. Apply cream to 2nd degree burns and cover them, give IV fluids
- c. Debridement of 2nd degree burns and
- d. Apply silver sulfadiazine then Vaseline ointment to all areas then discharge the patient

The correct answer is a

1st degree : epidermis + painful (no blister)

2nd degree : epidermis + partial dermis + painful _ blister

3rd degree : epidermis + full thickness dermis + painless

Rule of nine to estimate BSA :

1- Head and neck : 9%

- 2- Each upper arm : 9%
- 3- Each lower limb : 18%
- 4- Each post. & ant. Trunk : 18%
- 5- Perineum & genitalia : 1%

-Silver sulfadiazine and mafenide used for all types of burn
-supportive : tetanus and I.V narcotic can be used for all types of burn
- I.V fluid use only in (> 10% of BSA) in 2nd & 3rd degree of burn according parkland formula : (fluid in first 24h = 4 * wt. in kg * BSA . 50% in first 8 hours and another in next 16 hours)

In this patient 1st degree and 2nd degree < 10% (head and neck 9%) : so, not use fluid

913) 2 years old child with ear pain & bulging tympanic membrane, what is the diagnosis?

- a. Otitis media
- b. Otitis externa
- c. Otomycosis
- d. Bullous myringitis

The correct answer is a

914) Besides IV fluids, what is the most important drug to be given in anaphylaxis?

- a. Epinephrine
- b. Steroids
- c. ??? Other choices

The correct answer is a

915) An adult patient in 20s or 30s of age presents by history of 1 month of fever, 5 days of headache & 2 days of altered sensorium. On examination there is nuchal rigidity, then there is a table showing investigations which include

Hb: 10 g/dl

Blood WBC: 18,000

CSF Examination: WBCs elevated: 77% lymphocytes, 33% Neutrophils. Protein ???.

Glucose??

What is the diagnosis?

- a. Viral meningioencephalitis
- b. Tuberculous meningitis
- c. Ph.... Meningitis
- d. ???

Q is not complete , but with this scenario and MCQs , The correct answer is b

916) Regarding chronic fatigue syndrome, which is true?

- a. Antibiotics may reduce the symptoms
- b. Antidepressants may reduce the symptoms
- c. Rest may reduce the symptoms
- d. ???
- e. ????

Q IS not complete , but with these MCQs , the correct answer is b.

chronic fatigue syndrome:

characterizes by profound mental and physical exhaustion. In associated with multiple system and neuropsychiatric symptoms that last at least 6 mounth. Must be new (not life long) , must not be relived by rest, and must result in greater than 50% reduction in previous activity. Presentation with 4 or more of the following : poor memory / concentration, myalgia, arthralgia, sore throat, tender lymph node, recent onset headach, unrefreshing sleep, excessive tiredness with exercise. Treatment by : cognitive and excercise therapy .also, diet, physiotherapy, dietary supplements, antidepressants.

917) A patient complains of dry eyes, a moisturizing eye drops were prescribed to him 4 times daily. What is the most appropriate method of application of these eye drops?

- a. 1 drop in the lower fornix**
- b. 2 drops in the lower fornix**
- c. 1 drop in the upper fornix**
- d. 2 drops in the upper fornix**

918) A patient with penetrating abdominal stab wound. Vitals are: HR 98, BP 140/80, RR 18. A part of omentum was protruding through the wound. What is the most appropriate next step:

- a. FAST Ultrasound
- b. DPL (Diagnostic peritoneal lavage)
- c. Explore the wound
- d. Arrange for a CT Scan
- e. Exploratory laparotomy

The correct answer is e

919) A patient presents with loin pain radiating to the groin. Renal stones are suspected. What is the test that has the most specificity & sensitivity in diagnosing this condition?

- a. Noncontrast spiral CT scan of the abdomen**
- b. Ultrasound**
- c. KUB**
- d. Intravenous pyelography (IVP)**
- e. Nuclear Scan**

The correct answer is a

920) An old patient presents with history dizziness & falling down 1 day ago accompanied by history of Epigastric discomfort. He has very high tachycardia I think around 130-140 and BP 100/60. What is the diagnosis?

- a. Peptic ulcer**
- b. GERD**
- c. Leaking aortic aneurysm**
- d. ???**

The correct answer is c

921) A child is about to be given flu vaccine, what allergy should be excluded before giving the vaccine?

- a. Chicken
- b. egg
- c. Fish
- d. ???

The correct answer is b

922) Which of the following is proven to reduce the incidence of cancer?

- a. Salt
- b. Mineral water
- c. Vitamin D
- d. Fiber

The correct answer is c

923) A female patient with history of cyclic abdominal pain, inability to conceive, heavy menses, and examination showed tenderness & nodularity in uterosacral ligaments. What is the diagnosis?

- a. Endometriosis
-

924) A female patient on the 3rd week postpartum. She says to the physician that she frequently visualizes snakes crawling to her baby's bed. She knows that it is impossible but she cannot remove the idea from her head. She says she wakes up around 50 times at night to check her baby. This problem prevents her from getting good sleep and it started to affect her marriage. What is this problem she is experiencing?

- a. An obsession
- b. A hallucination
- c. A postpartum psychosis
- d. A Delusion

The correct answer is a

Obsession : persistent, unwanted, and intrusive ideas , thoughts, impulses or images

925) Regarding screening for cancer, which of the following is true?

- a. Screening for cervical cancer had decreased in recent years
- b. Screening for breast cancer had decreased in recent years
- c. Screening for Colorectal cancer is inadequate for the high-risk groups
- d. Screening for lung cancer has reduced the mortality rate of lung cancer
- e. Screening for tobacco use is now adequately done by health professionals

926) Regarding postpartum depression, what is the most appropriate intervention to reduce the symptoms?

- a. Include family in the therapy
- b. Isolation therapy
- c. Add very low doses of imipramine
- d. Encourage breastfeeding

The correct answer is a

927) Which of the following is a side effect of Buprione, a drug used to help smoking cessation:

- a. Arrhythmia
- b. Xerostomia
- c. Headache
- d. **Seizure**

The correct answer is d

928) A 60 years old patient with history of heart attack 6 weeks ago, complaining of not getting enough sleep. Psychiatric evaluation is unremarkable for depression or anxiety, what should be given to this patient?

- a. Amitriptyline
- b. Buspirone
- c. Buprione
- d. **Zolpidim**

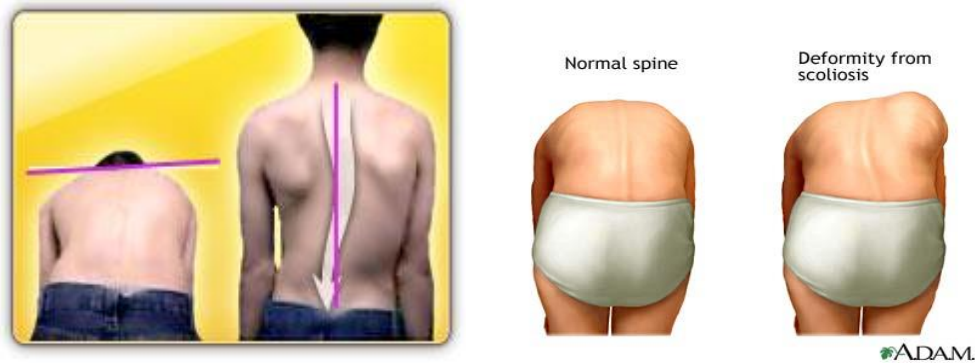The correct answer is d

929) A patient is asked to face the wall, bend his waist, and let his hands hang down without support. This test is used as a screening tool for which of the following?

- a. Lower limb asymmetry
- b. Rectal prolapsed
- c. **Scoliosis**
- d. ????

The correct answer is c

This test is called for (Adam's Forward Bend Test)



930) A patient presents with sore throat, cervical lymphadenopathy, mild splenomegaly, EBV antibodies are +ve. What is the diagnosis?

- a. **Infectious Mononucleosis (EBV)**

931) An old patient presents with knee pain, limitation of movement and quadriceps muscle atrophy. On examination there is limited range on movement, pain on movement & Crepitus. What is the diagnosis?

- a. **Osteoarthritis**
- b. Rheumatoid arthritis
- c. Ankylosing Spondylitis

The correct answer is a

932) A patient presents with long time history of knee pain suggestive of osteoarthritis. Now he complains of unilateral lower limb swelling and on

examination there is +ve pedal & tibial pitting edema. What is the next appropriate investigation?

- a. CXR
- b. ECG
- c. Echocardiography
- d. Duplex ultrasound of lower limb

The correct answer is d

Osteoarthritis relief by rest . So, immobility pt. can lead to DVT

933) Alopecia is a side effect of which antiepileptic?

- a. Phenytoin
- b. Carbamazepine
- c. Na Valproate
- d. ???

The correct answer is c

1-phenytoin : gingival hyperplasia, hirsuteism, ataxia

2-carbamazepine : agranulocytosis, hepatotoxicity, aplastic anemia

3- Na Valproate : transient hair loss.

934) Which of the following is an indication for tonsillectomy?

- a. Sleep apnea
- b. Asymptomatic large tonsils
- c. Peripharyngeal abscess
- d. Retropharyngeal abscess

The correct answer is a

935) Which of the following is a gram –ve rods that grow on charcoal yeast agar?

- a. **Legionella**
-

936) A 7 years old child had history of chest infection which was treated with antibiotics. The patient presented 6 weeks after cessation of antibiotics with

abdominal pain, fever and profuse watery diarrhea for the past month. Which of the following organisms is responsible for the patient's condition?

- a. Giardia Lamblia
- b. Clostridium Difficile
- c. Escherichia coli
- d. Clostridium Perfringens

[The correct answer is b](#)

937) Which of the following features of ulcerative colitis distinguishes it from crohn's disease

- a. Possible malignant transformation
- b. Fistula formation
- c. Absence of granulomas
- d. Colon involvement

[The correct answer is a](#)

938) A very very long scenario about a female patient with vaginal discharge "malodorous watery in character" with pH of 6 & +ve clue cells but there is no branching pseudohyphae. (He is telling you the diagnosis is vaginosis & there is no fungal infection) Then he asks about which of the following drug regimens should NOT be used in this patient:

- a. Metronidazole (PO 500 gm for 7 days)
- b. Metronidazole (PO 2 large dose tablets for 1 or 2 days)
- c. Metronidazole (IV or IM)
- d. Miconazole (PO)
- e. Clindamycin (PO)

[The correct answer is d](#)

This case is " **bacteria vaginosis**" and treatment by : metradinazole or clindamycine . avoid miconazole because it is antifungal

939) What is the condition that produces malodorous watery vaginal discharge with +ve clue cells in wet mount preparation slides:

- a. Bacterial vaginosis
- b. Vaginal Candidiasis
- c. Trichomonas vaginalis

d. Gonorrhea

[The correct answer is a](#)

940) Which of the following is the best treatment for Giardiasis:

a. Metronidazole

941) A woman with 9 weeks history of elevated erythematous wheals over all her body, she also has lip swelling. There is no history of recent travel or food allergy or drug ingestion, Diagnosis:

a. Chronic Angioedema & Urticaria

b. Contact Dermatitis

c. Solar Urticaria

d. Cholinergic Urticaria

e. Cold Urticaria

[The correct answer is a](#)

Chronic urticaria : if more than 6 months

Solar urticaria : due to sunlight

Cholinergic urticariae : due to brief increase in body temperature.

Cold urticaria : due to exposure to cold

942) A 17 years old male with history of mild intermittent asthma. Attacks occur once or twice weekly in the morning and no attacks at night. What should be the initial drug to give?

a. Inhaled short acting B2 agonist as needed

b. Inhaled high dose corticosteroid as needed

[The correct answer is a](#)

943) A child presented with sore throat. Culture from the throat revealed +ve meningococci. The patient is now asymptomatic. Which of the following should be done?

a. Reassurance

b. Rifampicin oral for 7 days

c. IM ceftriaxone 1 dose

d. Ceftriaxone oral

e. ??????

[The correct answer is c \(I'm not sure \)](#)

2-day regimen of oral rifampin or a single dose of IM ceftriaxone or a single dose of oral ciprofloxacin).

944) Which of the following increases the quality of the randomized controlled study & make it stronger:

- a. Systemic Assignment predictability by participants
- b. Open Allocation
- c. Including only the participants who received the full intervention
- d. Following at least 50 % of the participants
- e. Giving similar intervention to similar groups

[The correct answer is a](#)

945) A scenario about an infant who presented with difficulty breathing and sweating, examination shows hyperactive precordium with loud S2 and pansystolic murmur grade 3/6 best heard in the left 3rd parasternal region. What is the Diagnosis?

- a. VSD
- b. Mitral Regurgitation
- c. PDA
- d. Large ASD

[The correct answer is a](#)

946) Post IHD , your advise :

- a. Yoga
- b. isotonic exercise

???????????

947) very obese girl , what's the first step to reduce weight :

- a. increase water intake
- b. decrease calorie intake

[the correct answer is b](#)

948) 40 y/o male , presented with large hands , hepatomegaly diagnosis :

- a. acromegaly
- b. gigantism

[the correct answer is a](#)

949) course of facial nerve when comes out from stylomastoid ...

a. Deep to parotid gland & lateral to external carotid & retromandibular vein

950) old female with hemorrhoids for 10 years , no complication , your action ?

- a. observe
- b. surgery
- c. increase fiber diet

[the correct answer is c](#)

951) femal about 30y c/o abdominal pain related to menses (scenario going with endometriosis).....next step in dx:

- a. Laparoscopy
- b. U/S
- c. CT

[The correct answer is a](#)

Confirm diagnosis by laparoscopy , US & MRI can use but if normal can not exclude endometriosis .

952) female about 30y with breast cancer (given cbc –chem. And reavel low hb and hematocrite....) what is the next step in mangment:

- a. Staging
- b. Lumpectomy
- c. Mastectomy
- d. Chemotherapy

953) pt with open angle glaucoma and k/c of COPD and DM tt:

- a. Timelol
- b. betaxolol
- c. Acetazolamide

[the correct answer is c](#)

954) infant with runny nose and fever after that develop dysnea ,wheezing with working accessory muscles and chest retractions with cyanosis, temp 38 dx:

- a. Viral pneumonia
- b. Bacterial pneumonia
- c. Bronchiolitis

The correct answer is c

955) 34y female with HIV pap smear negative, about cervical cancer screening :

- a. After 3m if negative repeat after 6m
- b. After 6m annually
- c. After 1y.....annually

The correct answer is b (I'm not sure), may be c .

- Screening should begin no later than age 21.
- Screening should begin earlier than age 21 if the patient is sexually active. In this case, it should start 3 years after initiation of vaginal intercourse.
- Once initiated, screening should be performed annually if a traditional, glass-slide-based technique is used. If liquid medium is used, Pap smear screening may be performed every other year.
- After age 30, for women who have had 3 consecutive, normal Pap smears, screening frequency may be reduced to every two to three years.
- Women who are HIV positive, immunocompromised due to disease or medication, or are DES daughters, should continue annual screening.
- Screening may stop following a total hysterectomy (including the cervix), if the patient is at low risk, and has had three consecutive normal Pap smears within the last 10 years.

- High risk patients, including those with a history of cervical cancer, DES exposure in-utero, HIV positive, immunocompromised from medication, and those tested positive for HPV, should continue to be screened indefinitely.
- Screening may stop after age 70, if the patient is low risk, and has had three normal Pap smears over the last 10 years.
- Screening may be omitted in the case of women with life-threatening or other serious illness

956) which drug increase incidence of reflux oesophagitis:

- a. Theophylline
- b. Amoxicilline
- c. Metoclopramide
- d. Rantidine
- e. Lansoprazole

[The correct answer is a](#)

957) most effective ttt of cluster headach:

- a. Ergotamine nebulizer
- b. S/C Sumatriptan
- c. 100% O2
- d. IV Verapamil

[The correct answer is c](#)

958) old pt. with HTN and migraine ttt:

- a. B blockers
- b. ACE I
- c. Ca blockers

[The correct answer is a](#)

959) lactating women 10 days after delivery developed fever ,malaise, chills tender Lt breast with hotness and small nodule in upper outer quadrant with axillary LN .Leukocyte count was $14 \times 10^9/L$ dx:

- a. Inflammatory breast cancer
 - b. Breast abscess
 - c. Fibrocystic disease
 - d. ????
 - ???????
-

960) newborn with fracture mid clavicle what is true:

- a. Most cases cause serious complication
- b. Arm sling or figure 8 sling used
- c. Most patient heal without complications

The correct answer is c

-most clavicles fracture in newborn no need to treatment apart from careful handling. If the fracture is displaced and baby in pain, simple sling is require.

961) 70y male with osteoporosis the T score of bone densometry would be :

- a. 3.5
- b. -2.5
- c. -1
- d. 2
- e. 3.5

The correct answer is b

- The T score is the number of standard deviation (SD) a patient's BMD deviated from the mean.
 - **T score > (- 1) : normal BMD**
 - **T score (-1 to -2.5) : ostopenia**
 - **T score < (-2.5) : osteoprosis**
-

962) what is the most complication after hestectomy:

- a. Ureteral injury
- b. Pulmonary embolism
- c. Haemorrhage

[The correct answer is c](#)

963) young female with BMI 18 , fine hair all over body , feeling of she is fat , doesn't eat well with excessive exercise.....

- a. Anorexia nervosa?
- b. Body dysmorphic disorder
- c. Bulimia nervosa

[The correct answer is a](#)

964) what's advantage of mature human milk over cow's milk:

- a. More protein
- b. More Iron content
- c. More calories
- d. More fat

[The correct answer is b](#)

965) young male c/o of deformity of jaw .past h/o of nasoplasty and blepharoplasty
O/E nothing abnormaldx:

- a. Body dysmorphic syndrome

966) the most common cause of non-traumatic subarachnoid haemorrhage:

- a. Rupture aneurysm
- b. Vessels abnormality
- c. Hypertension

[The correct answer is a](#)

-Most common causes of subarachnoid hemorrhage are trauma and berry aneurysm

967) Pt. with chest pain and s.o.b decreased by leaning forward . O/E friction rub and increased JVP >>>> (a case of pericardial effusion) ECG will show:

- a. ST changes
- b. Low voltage
- c. Increase PR interval

ECG changes during pericarditis : diffuse ST elevation , PR depression followed by t-wave inversion , and low voltage.

968) The causative organism of pseudomembranous colitis is:

- a. Clostridium difficile

969) scenario about arthritis (I couldn't remember the details) but Joint aspirate reveal Gram negative diplococcidx:

- a. *Neisseria gonorrhoea*

N. gonorrhoeae : gram negative diplococci and can also cause conjunctivitis, pharyngitis, proctitis or urethritis, prostatitis and orchitis.

970) Vertigo & is caused by which of the following drug ?

- a. Aphotercine B
b. Pnicilline reaction
c. INH

971) Baby with red macule & dilated capillary on the rt side of the face

Sturge-Weber Syndrome or Nevus Flammeus (*one of them will come*)

Don't choose milia or cavernous haemangioma

972) A 25 year old secondary school teacher that every time enters the class starts sweating and having palpitation, she is a fire to give wrong information and be unparsed. What is the diagnosis:

- a. Specific Phobia
b. Social Phobia

The correct answer is b

973) At which chromosome is the cystic fibrosis gene:

- a. Long arm chromosome 7
b. Short arm chromosome 7
c. Long arm chromosome 8
d. Short arm chromosome 8
e. Long arm chromosome 17

The correct answer is a

974) Regarding hepatocellular carcinoma (Hepatoma) Which is true:

- a. More common in females
- b. ..
- c. ..
- d. The most common cancer in Africa and Asia
- e. Increase risk in chronic liver disease

[The correct answer is e , chronic disease especially Hepatitis B](#)

975) A patient is having a 2 year history of low interest in life, he doesn't sleep well and can't find joy in life, What is the most likely diagnosis:

- a. Dysthymia
- b. Major depressive disorder
- c. Bipolar disorder
- d. ..
- e. ..

[The correct answer is a](#)

976) What is the mechanism of OCD drugs:

- a. Increase availability of Serotonin
- b. Decrease production of Serotonin
- c. Increase production of Serotonin
- d. .. Serotonin
- e. .. Serotonin

[The correct answer is a](#)

977) What is the MOST accurate test to detect early pregnancy:

- a. ..Serum BHCG
- b. ..
- c. Urine pregnancy test
- d. Ultrasound
- e. ..

[The correct answer is a](#)

978) A case of a patient with thin cervix and little amount of cervical mucus, how would you treat her: ?????

- a. Estrogen injections

979) The most common cause of chronic interrupted rectal bleeding is:

- a. Diverticulosis
- b. Hemorrhoids

The correct answer is b

980) A child is having a croup early morning, the most common cause is:

- a. Post nasal drip

981) A burn patient is treated with Silver Sulfadiazine, the toxicity of this drug can cause:

- a. Lycosytosis
- b. **Neutropenia**
- c. Electrolyte disbalance
- d. Hypokalemia
- e. ..

The correct answer is b , side effect of sulfadiazine

982) A case scenario about a patient who had appendectomy, after that he has abdominal pain and constipation and absent bowel sound, the most likely cause is:

- a. Ilus paraticus

Q is not complete

983) A case scenario describing a patient who had a right chest trauma than developed tension pneumothorax, the immediate management is:

- a. Insert a needle in the second intercostal space
- b. Insert a needle in the fifth intercostal space
- c. Give IV antibiotics
- d. ..
- e. Insert a tube in the fifth intercostal space

[The correct answer is a](#)

984) A patient that have a penile ulcer that healed after that he developed a palm and sole rash, the most likely cause is:

- a. Syphilis

[Q is not complete](#)

985) A case scenario about a patient who has on and off episodes of abdominal pain and was found to have multiple gallstones, the largest is 1 cm and they are not blocking the duct, What will you do:

- a. Give pain killers medication
- b. Remove gallbladder by surgery

[Q is not complete , but with these MCQs , the correct answer is b](#)

986) Most common symptoms of soft tissue sarcoma :

- a. Paralysis
- b. On growing mass
- c. Pain
- d. ..

[The correct answer is b](#)

987) Patient use illegal drug abuse and the blood show RNA virus. Which hepatitis

- a. A

- b. B (DNA)
- c. C
- d. E

[The correct answer is c , RNA virus transmitted by blood id HCV](#)

988) A case scenario about bronchial carcinoma, which is true: ????

- a. The most common cancer in females
- b. Squamous cell carcinoma spreads faster
- c. Adenocarcinoma is usually in the upper part
- d. Elevation of the diaphragm on the x-ray means that the carcinoma has metastasize outside the chest
- e. Bronchoscopy should be done

[The correct answer is c](#)

989) old female with pubic itching with bloody discharge, then she developed pea shaped swelling in her labia, most likely:

- a. Bartholin cyst
- b. Bartholin gland carcinoma
- c. Bartholin abscess
- d. ..

[The correct answer is c](#)

990) Patient has decrease visual acuity bilateral , but more in rt side , visual field is not affected , in fundus there is irregular pigmentations and early cataract formation . what you will do

- a. Refer to ophthalmologist for laser therapy
- b. Refer to ophthalmologist for cataract surgery
- c. ..

[The correct answer is a](#)

991) Inflammatory bowel disease is idiopathic but one of following is possible underlying cause:
a. Immunological

992) pregnant lady delivered Anencephaly till birth occurrence of neural tube defect in next pregnancy
a. 8%
b. 2%
c. 10%
d. 20%

The correct answer is b, (2 – 4 %)

993) typist the inner atrophy, +ve Tophan sign
a. Median nerve
b. Ulnar
c. Brachial

The correct answer is a

994) painful pile
a. Exision and drainage
b. Sitz bath and steroid supp
c. Ab
d. Fiber food and analgesics

The correct answer is a

995) 39 years old HIV patient with TB receive 4 drugs of tt after one month
a. Continue 4 drugs for 1 years
b. Continue isoniazide for 9 months
c. Continue isoniazide for 1 year

The correct answer is a

996) female not married with normal investigation except FBS=142.
RBS196. so tt
a. give insulin subcutaneous
b. advice not become married
c. barrier contraceptive is good
d. BMI control

The correct answer is d

997) Entamoeba histolytica cysts are destroyed best by:

- a. Boiling
- b. Iodine added to water
- c. Chlorine added to water
- d. Freezing

The correct answer is a

998) A scenario about an old male with symptoms suggesting parkinsonism such as difficulty walking, resting tremors and rigidity in addition to hypotension. Then he asks about what is the most common presenting symptom of this disease

- a. Rigidity
- b. Tremors
- c. Unsteady Gait
- d. Hypotension
- E. ???

The correct answer is b

998) Regarding postpartum Psychosis:

- a. Recurrences are common in subsequent pregnancies
- b. It often progresses to frank schizophrenia
- c. It has good prognosis
- d. It has insidious onset
- e. It usually develops around the 3rd week postpartum

The correct answer is a

999) Gastricomy post-op 1 day. He have temperature 38.8 & pulse 112. What is the most common cause ?

- a. wound infection.
- b. inflammatory mediator in the circulation.
- c. UTI
- d. normal

the correct answer is a or b

most common causes of post-operation fever : (6 w)

- 1- W ound
- 2- Wine = pneumonia or atelectasia
- 3- Water = UTI
- 4- What happen = transfusion
- 5- Walk = DVT
- 6- Wonder drug = aspirin, erythromycin , izonizide

Immediately (24 h) : post-op inflammation , wound infection , transfusion , streptococcus

Acute (3 – 7 days) : pneumonia

1000) Malaria ?

- the most common cases is caused by Plasmodium falciparum.

.....

1001) Polyarthralgia rheumatica. What is the thing that suggest it rather than ↑ ESR & C-reactive protein:

- a. proximal muscle weakness
- b. proximal muscle tenderness

the correct answer is a

.....

1002) The cause of insulin resistance in obese is:

- a. ↑ insulin receptors kinase activity
- b. ↑ number of insulin receptor
- c. ↑ circulation of anti-insulin
- d. ↓ insulin production from the pancreas
- e. ↓ post-receptor action

[the correct answer is e \(I'm not sure \)](#)

1003) Pt came with total bilirubin: 5.8 & direct bilirubin: 0.4

- a. Guillain–Barré syndrome
- b. Dubin-junson syndrome
- c. Biliary sclerosis
- d. Crigler-Najjar syndrome
- e. Gilbert Syndrome

[the correct answer is e](#)

1004) Pt complaining of hypotension & bradycardia. Electrolytes show: ↓Na, ↑K, ↑Cl, ↑Urea. So the cause of this is:

- a. hyponatremia
- b. hyperkalemia
- c. hyperchloremia
- d. uremia

the correct answer is a (not sure)